Immunosuppressive Diseases in Commercial Chickens

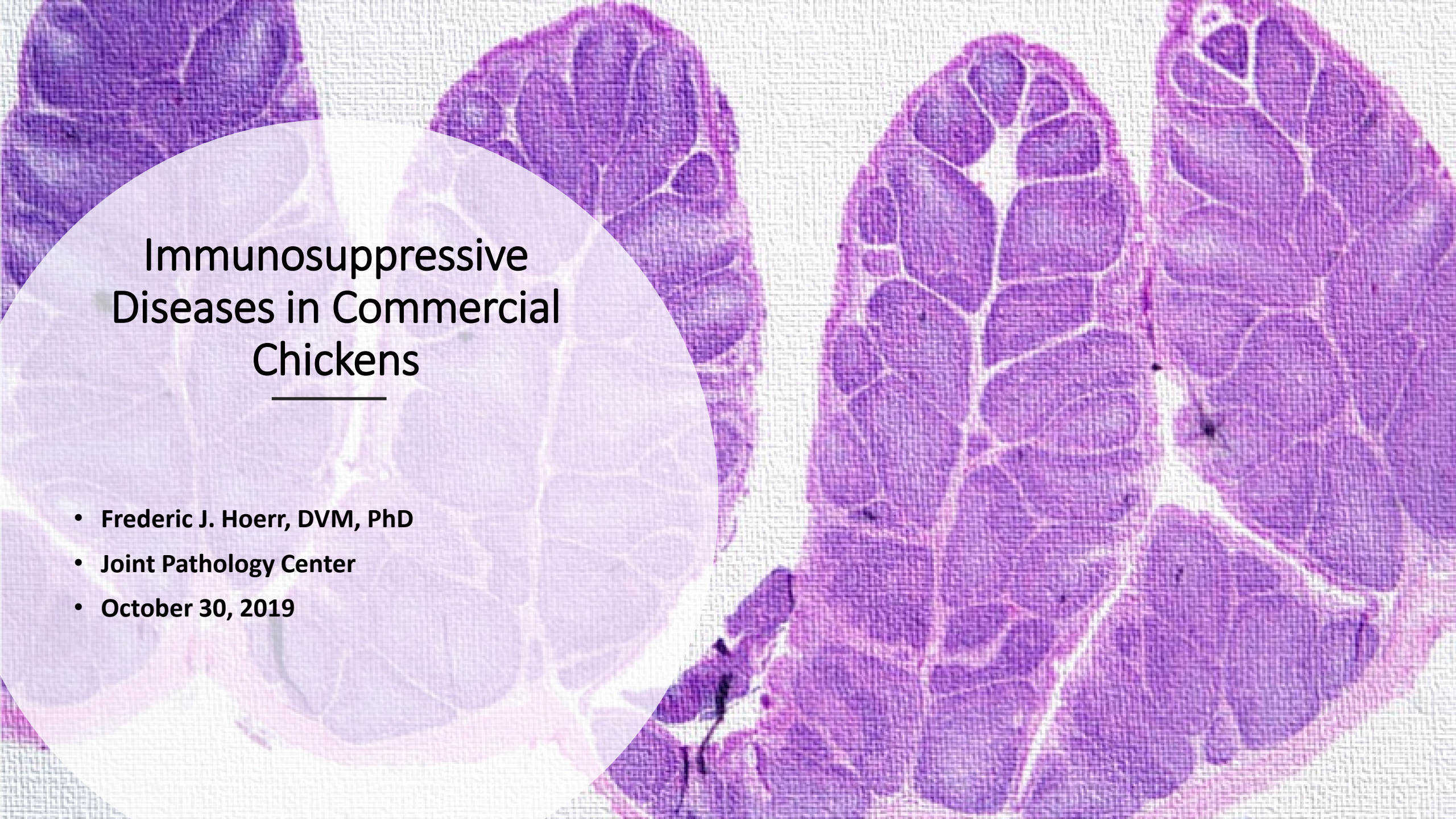

- **Frederic J. Hoerr, DVM, PhD**
- **Joint Pathology Center**

- **October 30, 2019**

Bursa of Fabricius and B lymphocytes

- The embryonic bursa is populated by precursor embryonic cells from yolk sac and liver
- B Lymphocytes develop in medulla and migrate to cortex
- Most are destroyed by MHC selection
- Migrate to blood stream and populate secondary tissues
- 12,000 follicles, each follicle has 2-500,000 cells

Fellah et al, Avian Immunology 2nd, 2014, 45-63

Sci Rep. 2018; 8: 16905. Published online 2018 Nov 15. doi: 10.1038/s41598-018-34897-4; Kwang Hyun Ko, et al.

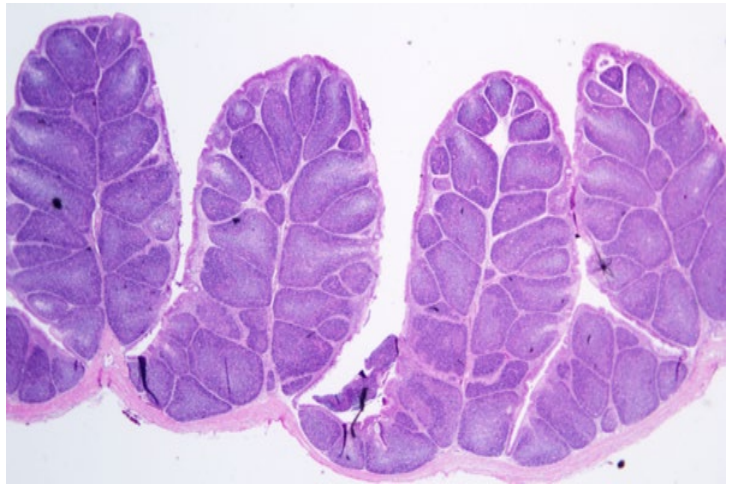

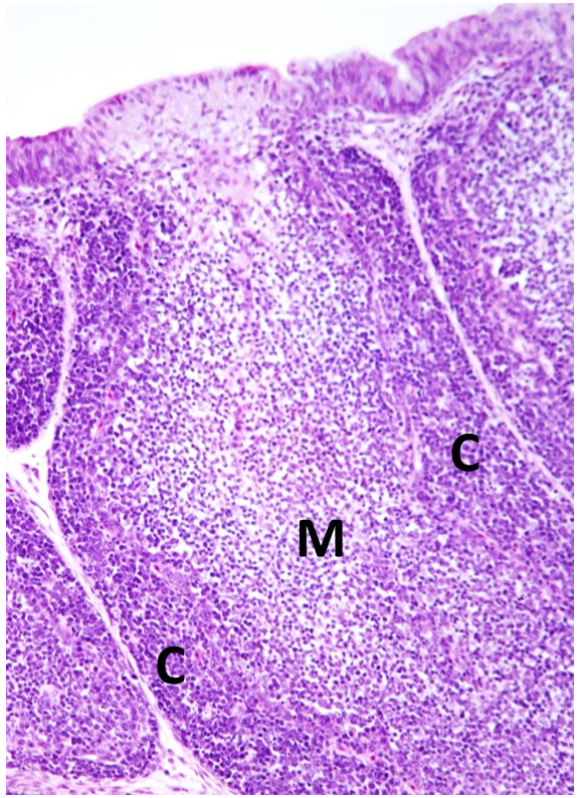

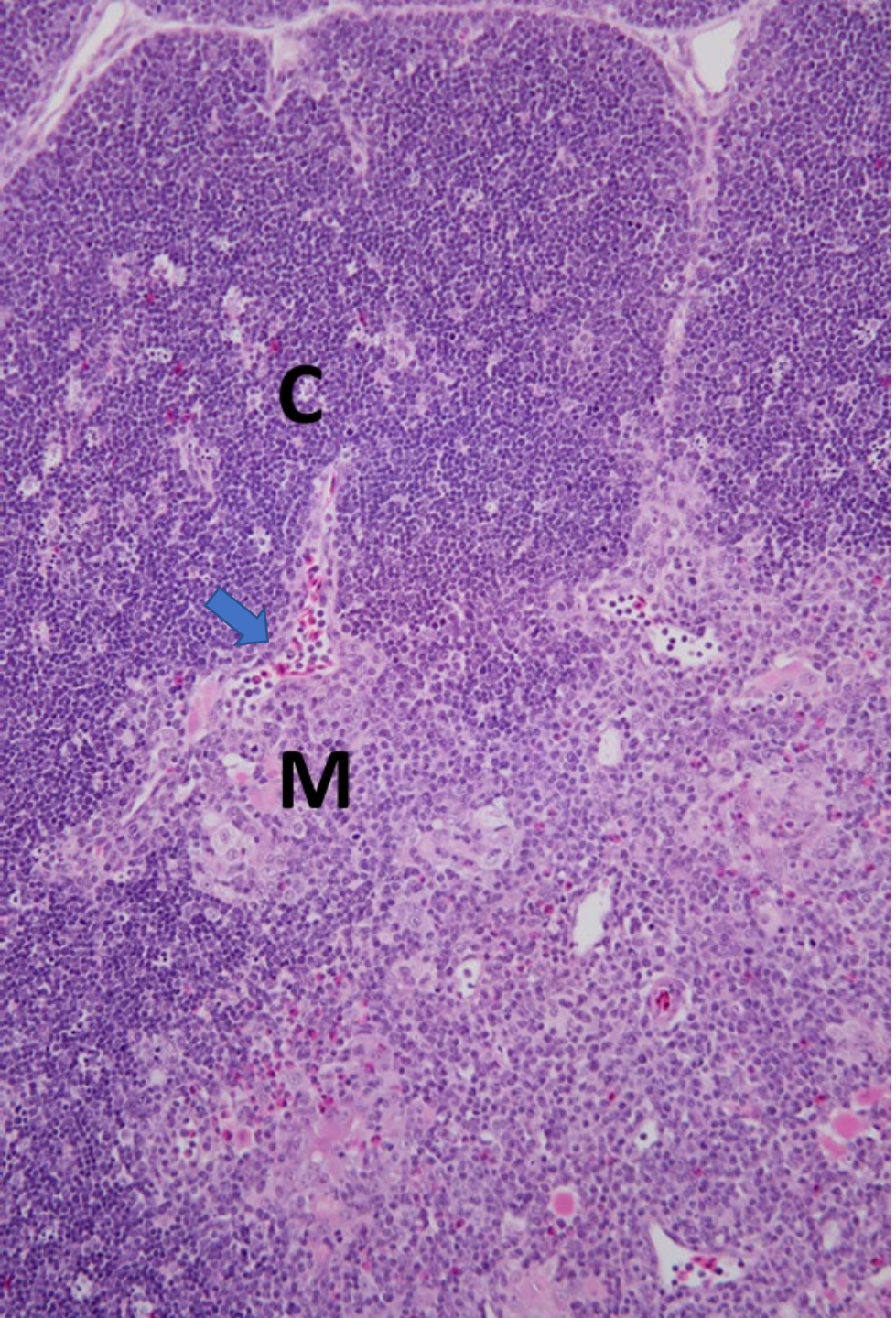

Thymus

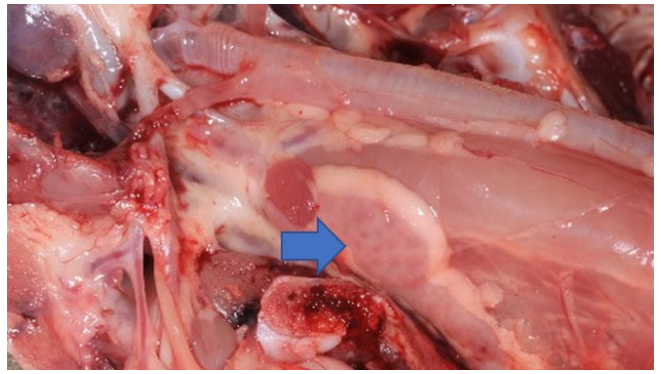

- T-cells mature while traversing from cortex to medulla
- 95% of developing T lymphocytes are destroyed in development through Major Histocompatability Complex selection
- Mature T lymphocytes depart through venules at cortico-medullary junction
  - Distribute to secondary lymph organs: spleen, Peyer's patches, cecal tonsil
- Delicate balance of mature T Lymphocyte production, development, and supply to secondary organs – easily disrupted

http://bszm.elte.hu/anatomy/birds/16/

Spleen

Periarteriolar lymphoid sheath (PALS), rich in T lymphocytes that are seeded by the thymus

Germinal centers composed of B Lymphocytes, seeded by the bursa, and plasma cells

Ellipsoid containing lymphocytes and reticular cells

Red pulp

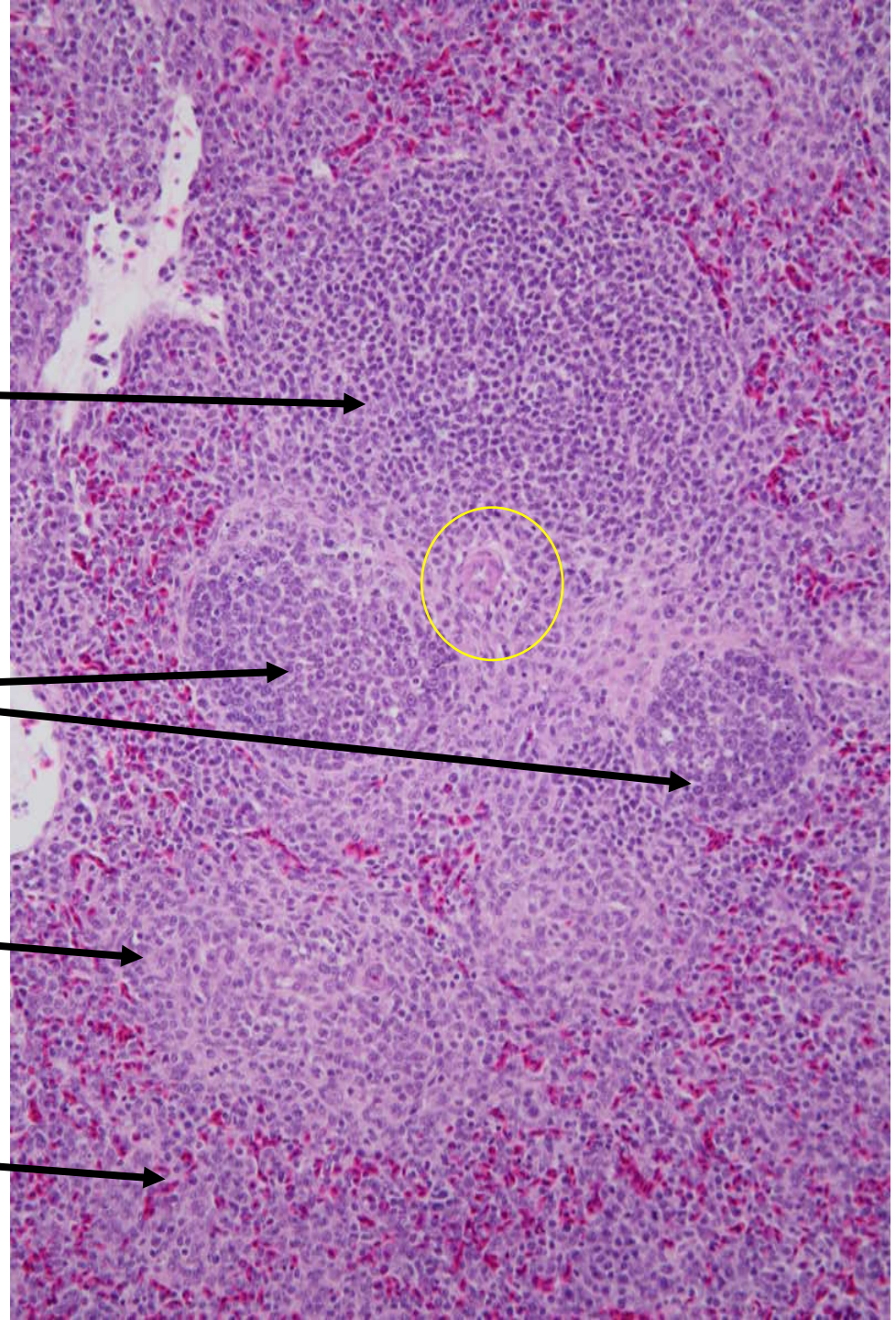

Recognizing Immunosuppression

- Poor/harsh vaccination responses
- Exaggerated morbidity/mortality
- Early stress, later problems
  - Viral enteritis - Runting stunting syndrome
- Early exposure to immunosuppressive diseases
  - Bursal disease
  - Chicken infectious anemia
  - Marek's disease
  - Newcastle
  - Reovirus (Viral Arthritis), Reticuloendotheliosis, ALV-J
- Diseases associated with immunosuppression
  - Inclusion body hepatitis, respiratory disease, coccidiosis, gangrenous dermatitis

Infectious Bursal Disease – Classical and Variant

R. W. Winterfield

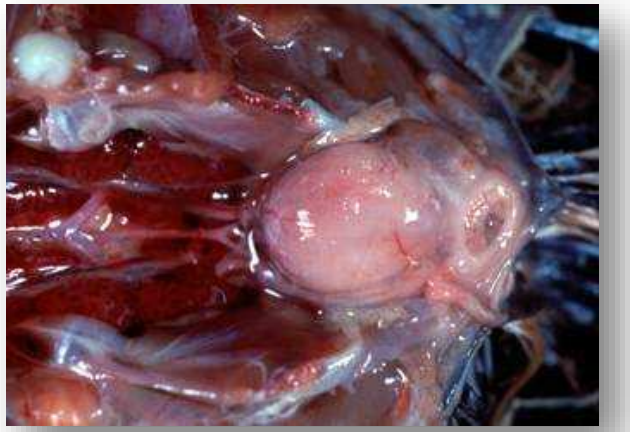

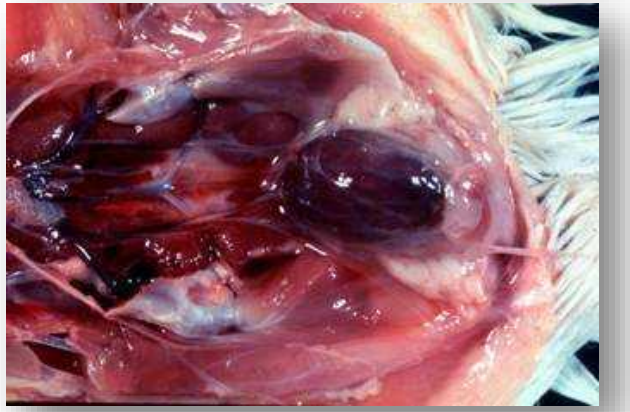

Delaware Variant

Very Virulent Bursal Disease (vvIBD)

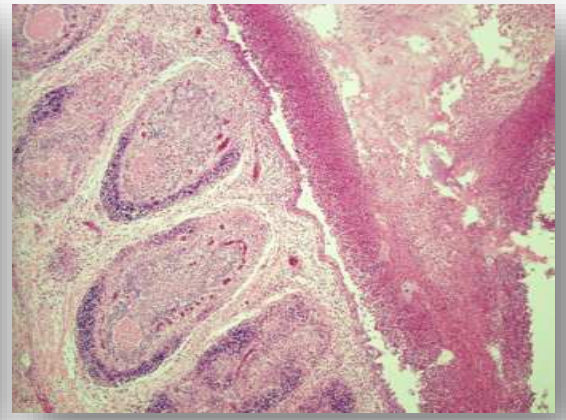
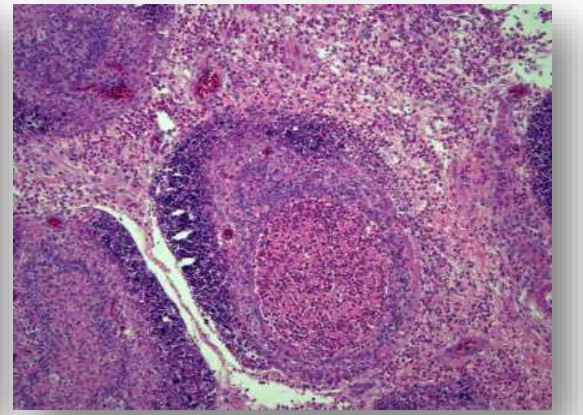

Chicken Infectious Anemia



Blue Wing
Ala Azul

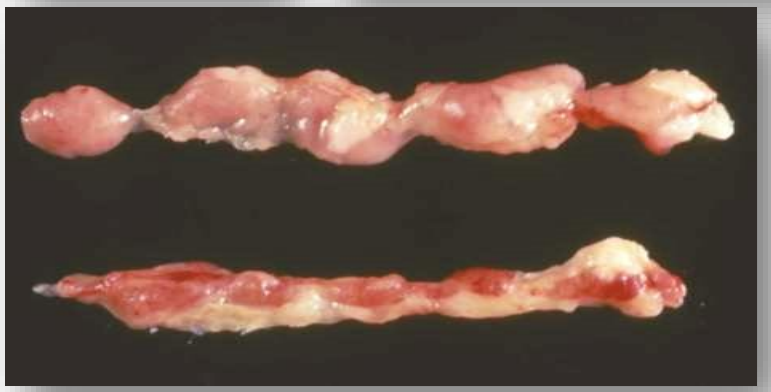

Crowther et al, J Virol. 2003 77: 13036–13041

AAAP Slide Set

Marek's Disease

Immunosuppression → Skin lymphoma and tumors

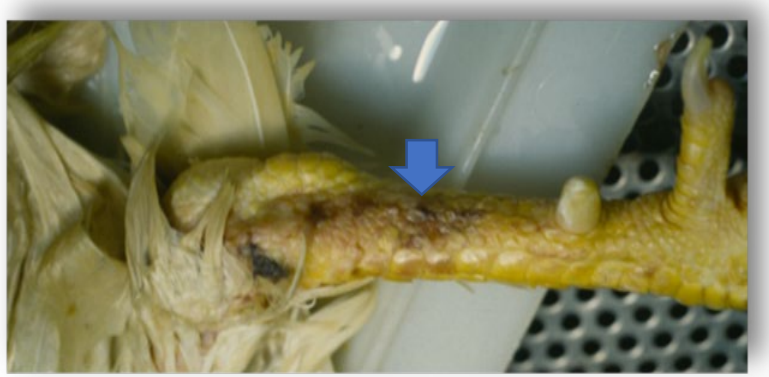

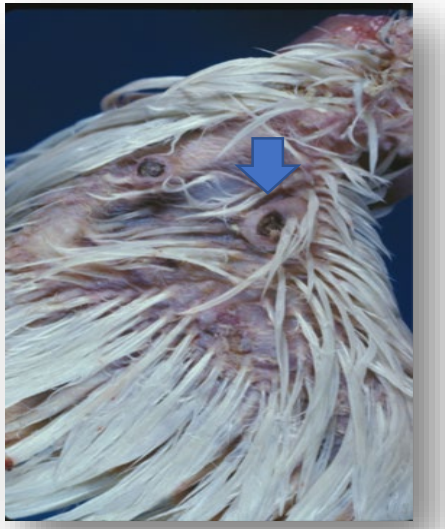

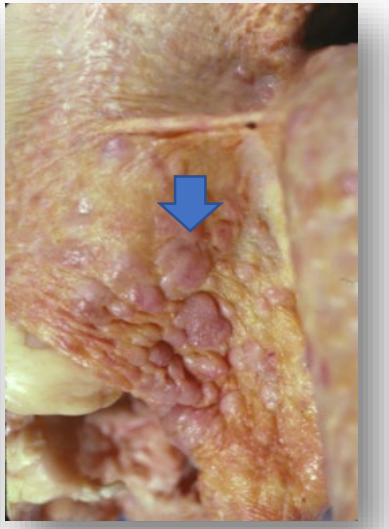

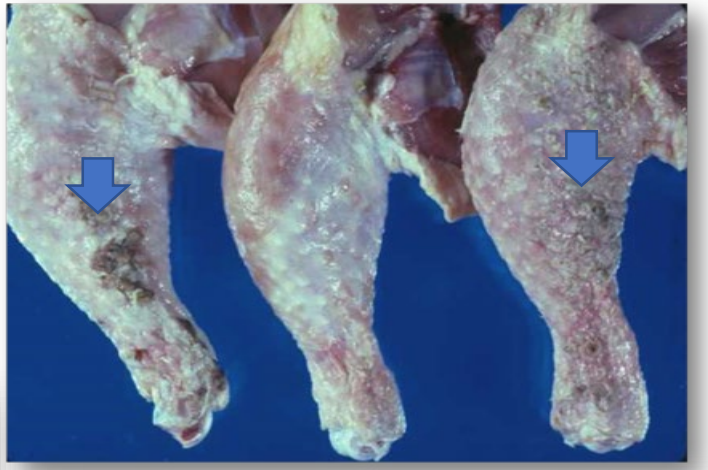

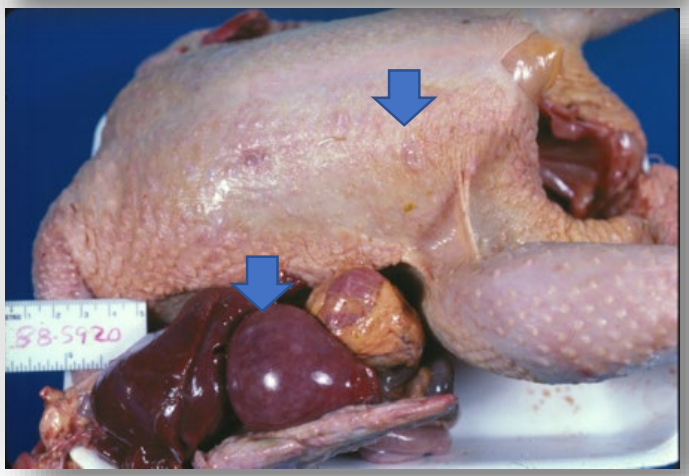

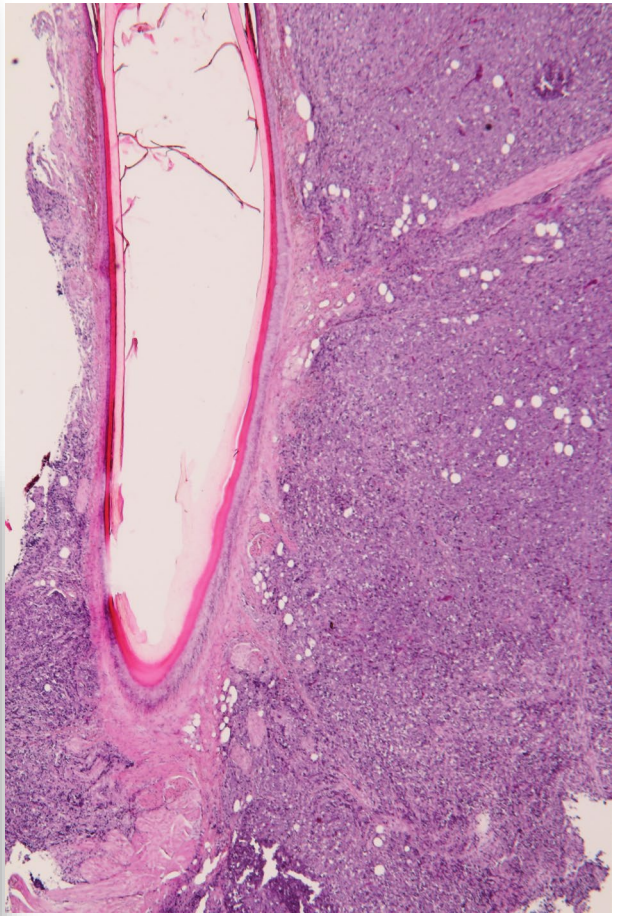

Marek's Disease Immunosuppression

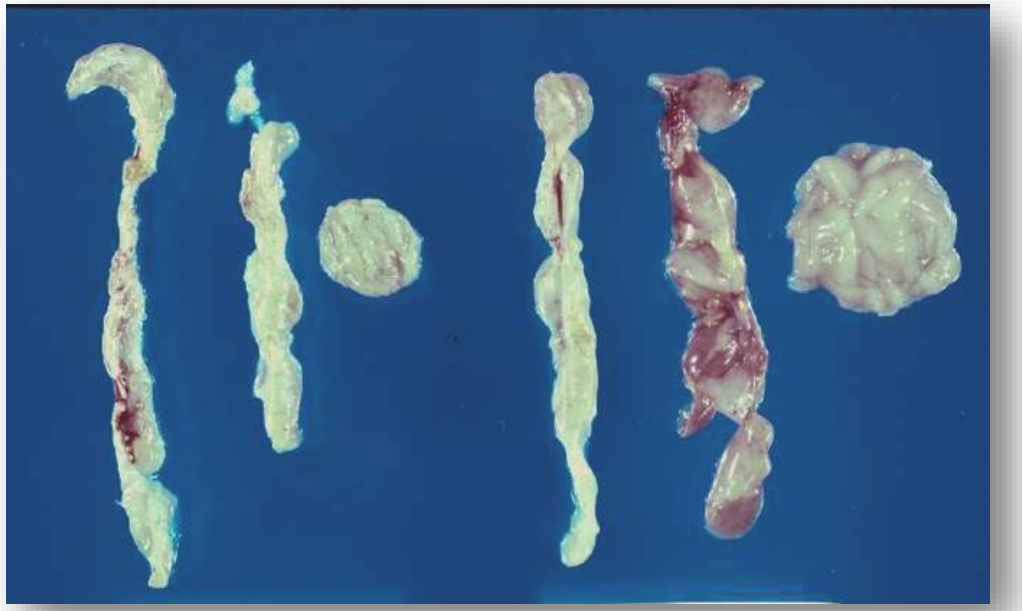

Marek's Disease Control

- Occurs at a young age
- Difficult to confirm
- Assume early immunosuppression if Marek's tumors or clinical disease are present

Broiler Viral Enteritis
“Runting Stunting Syndrome”

06.1029

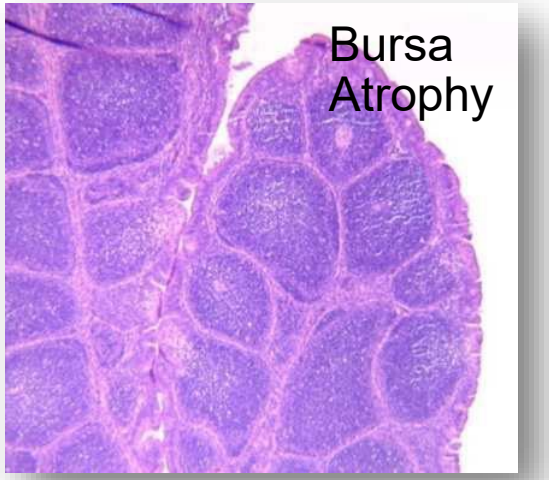

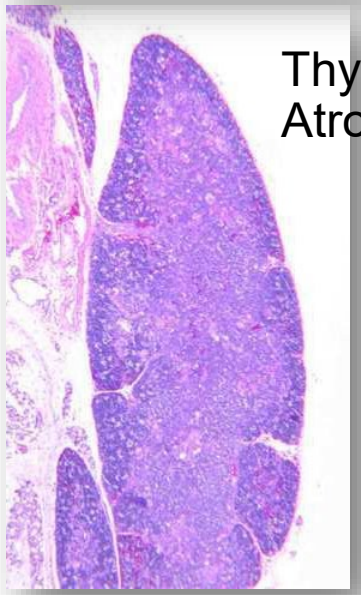

Viral enteritis diagnosis: Retrospective PCR and Immune System Histopathology

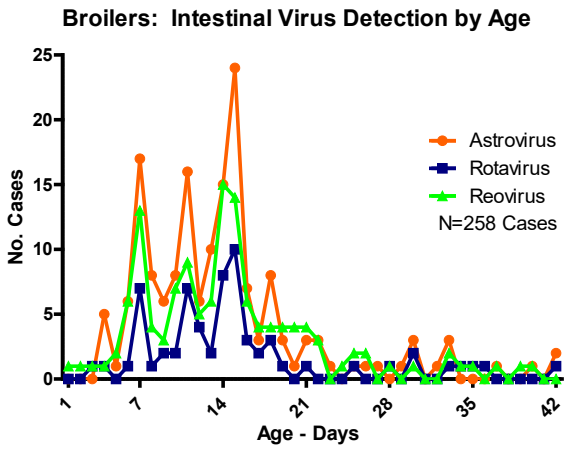

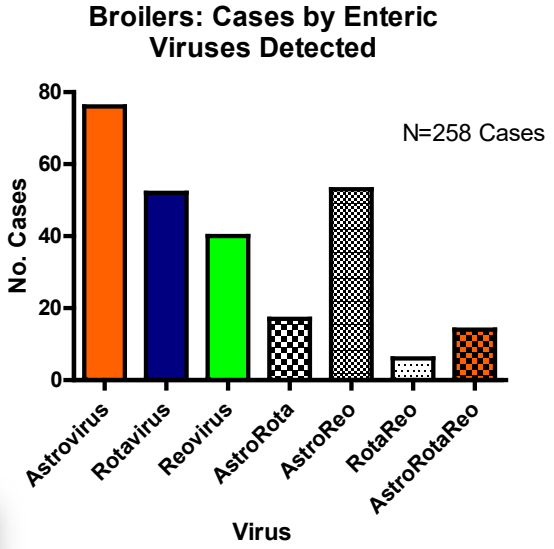

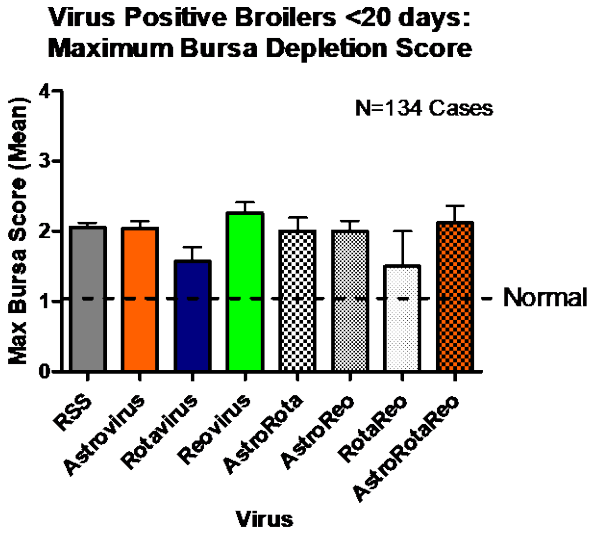

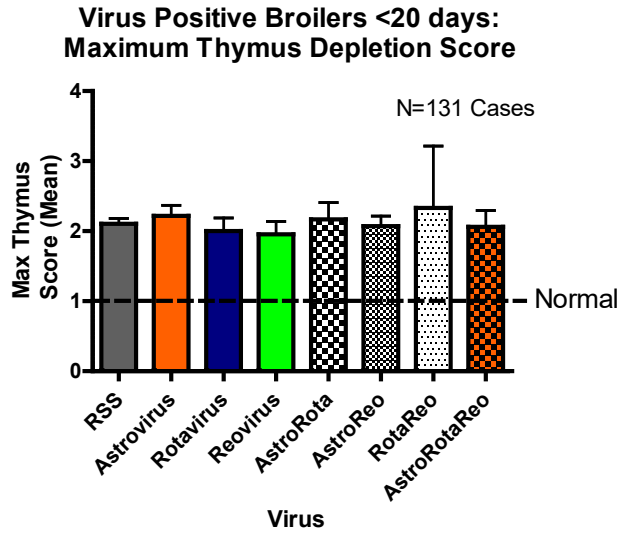

Enteric Virome Metagenomic Analysis: SPF Sentinals on 6 broiler farms

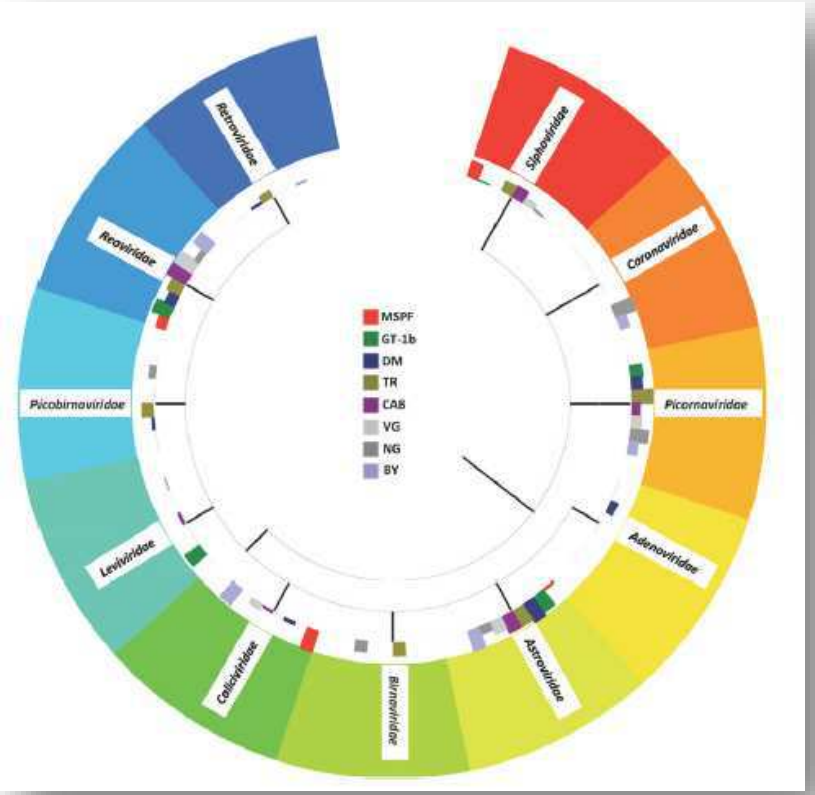

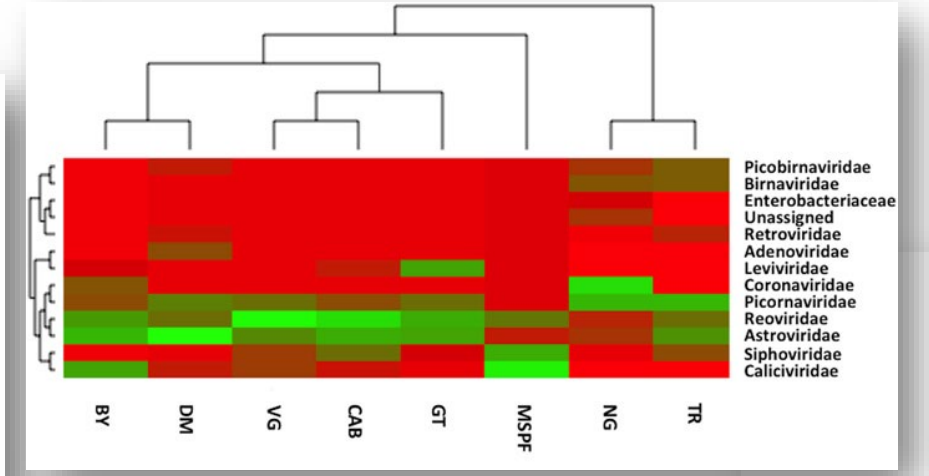

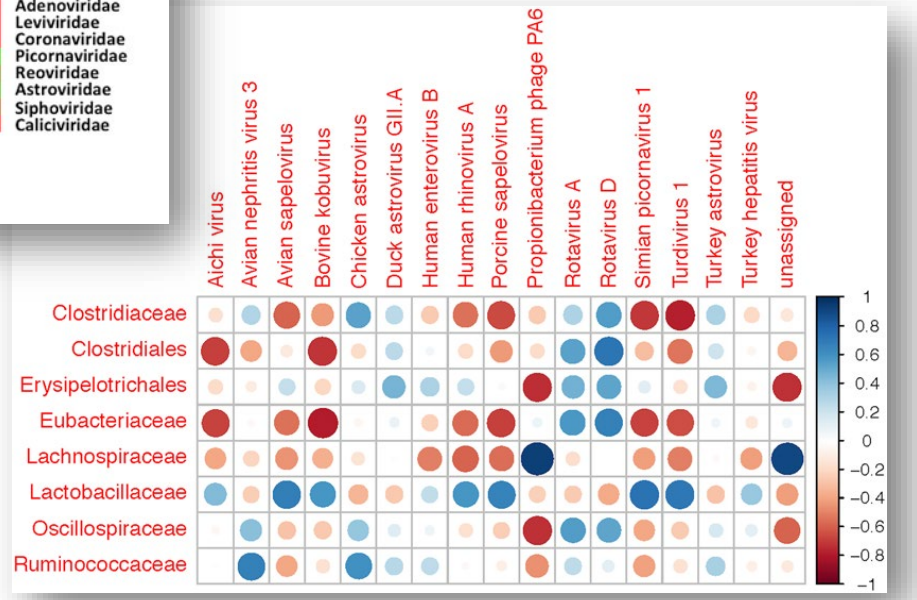

Day JM, Oakley BB, Seal BS, Zsak L (2015) Comparative Analysis of the Intestinal Bacterial and RNA Viral Communities from Sentinel Birds Placed on Selected Broiler Chicken Farms. **PLoS ONE 10(1): e0117210. doi:10.1371/journal.** pone.0117210

Experimental Mycotoxicosis: Target Organs

Toxin	Liver	Kidney	Immune	Skin/Oral	Other
Aflatoxin **Sterigmatocystin** **Cyclopiazonic acid**	+++	+	+		+
Trichothecenes **Fusarochromanone** **Moniliformin**	+		+++	+++	++
Ochratoxin	++	+++	+		+
Citrinin		+++			
Oosporein		+++			
Ergot				+++	++

DAS - Diacetoxyscirpenol

Mycotoxin Immunosuppression

Toxin	Lymphoid Atrophy	Cell Mediated	Humoral	Disease Interaction
Trichothecenes (T-2. DAS, Others)	+	+	+	+
Moniliformin		+	+	
Fumonisins	+	+		
Aflatoxin	+	+	+	+
Ochratoxin	+	+	+	+
Citrinin	+			
Cyclopiazonic Acid	+			
Sterigmatocystin	+			

Broiler, 50 days, hepatosis

- Bile duct proliferation
- Differential diagnosis
  - Hepatotoxic mycotoxins
  - Aflatoxin, cyclopiazonic acid, sterigmatocystin
- Implications
  - Damaged liver
  - Altered hepatic processing of nutrients
  - Immunosuppression

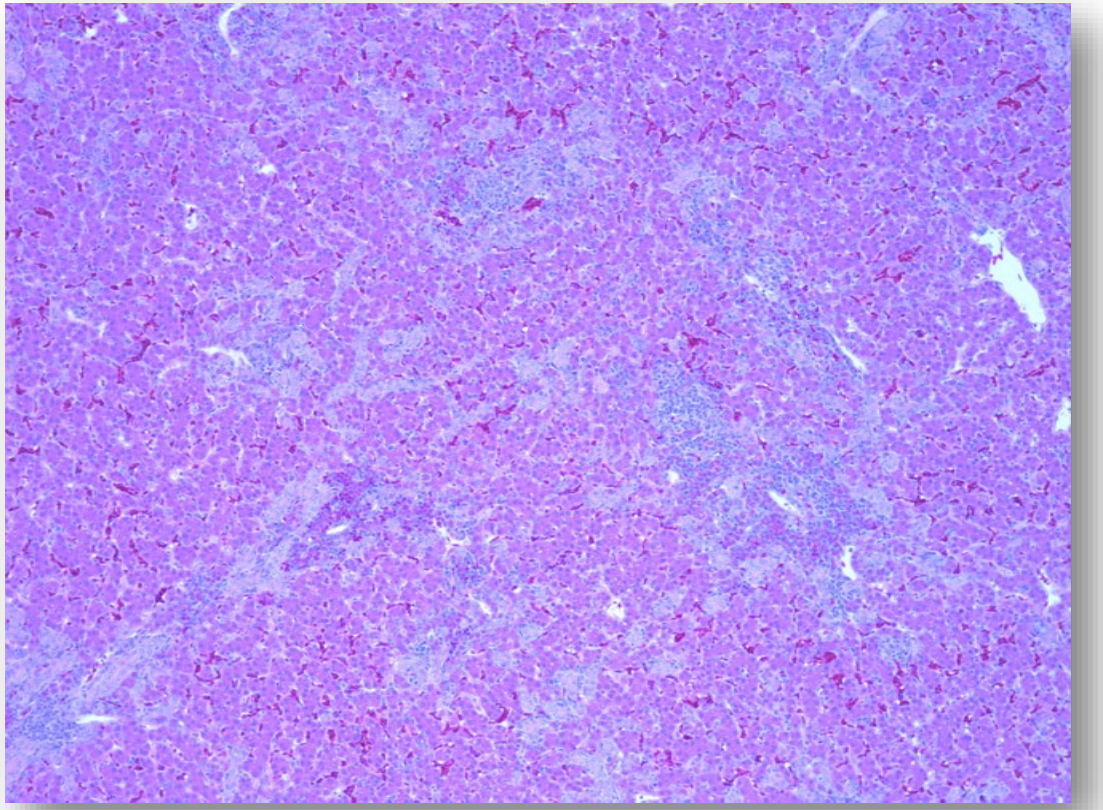

Variant Reovirus - Challenge Study

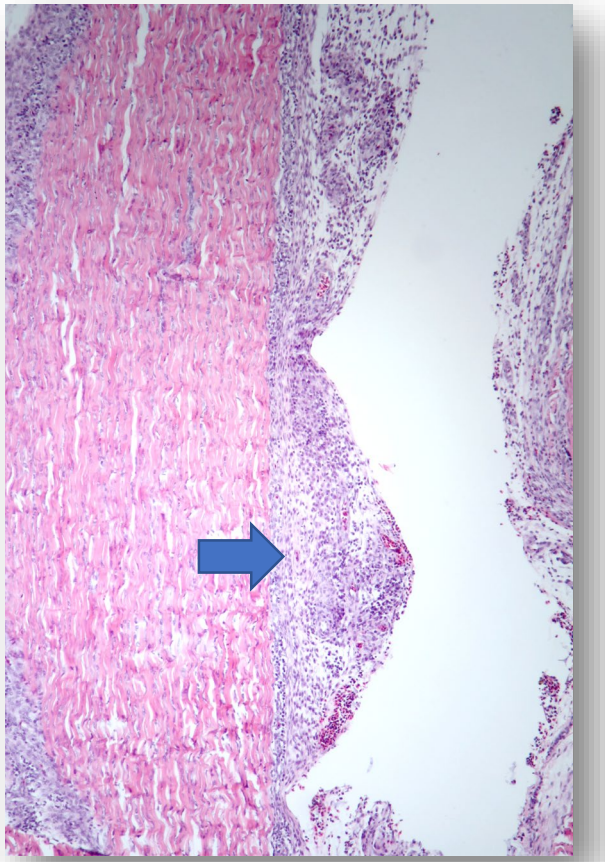

Tendon

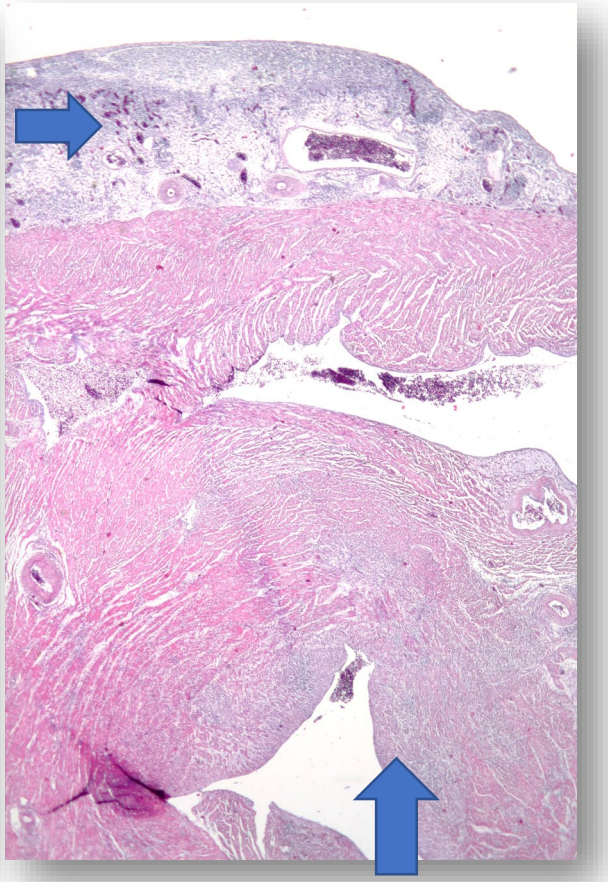

Heart

Bursa follicular lymphoid depletion

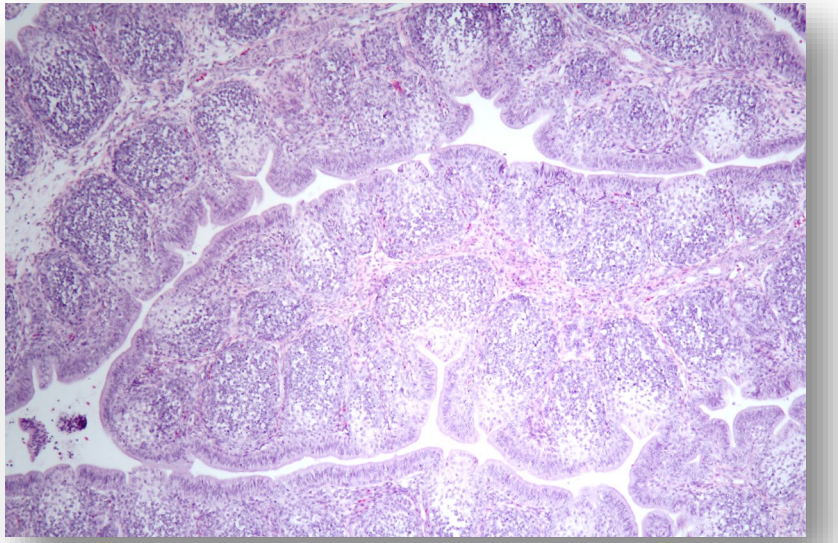

Thymus cortex lymphoid depletion

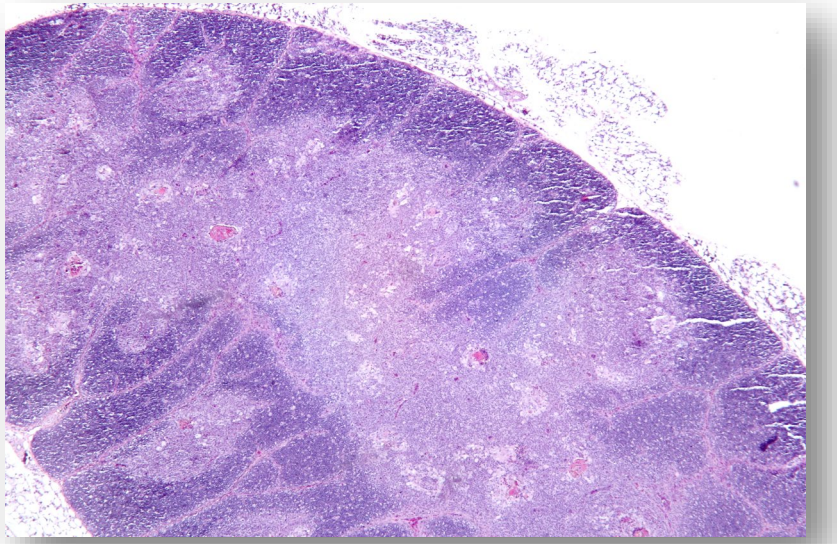

Newcastle Disease - Lymphocyte Necrosis and Depletion

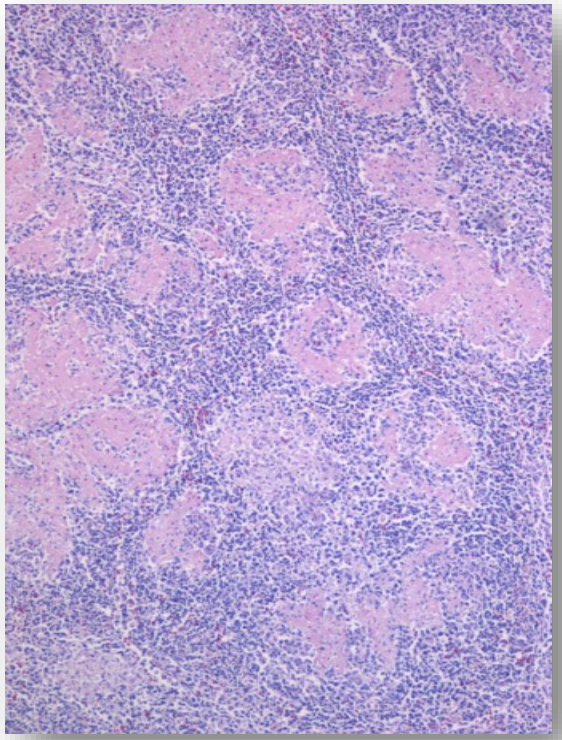

Spleen

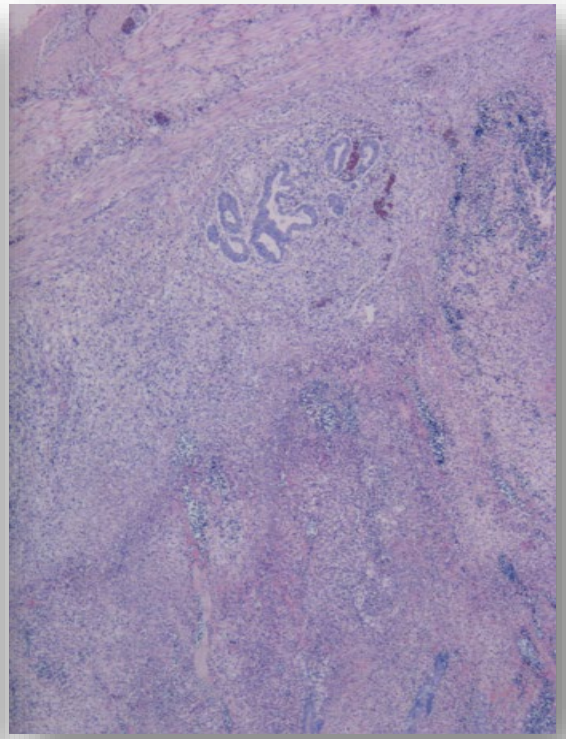

Cecal tonsil

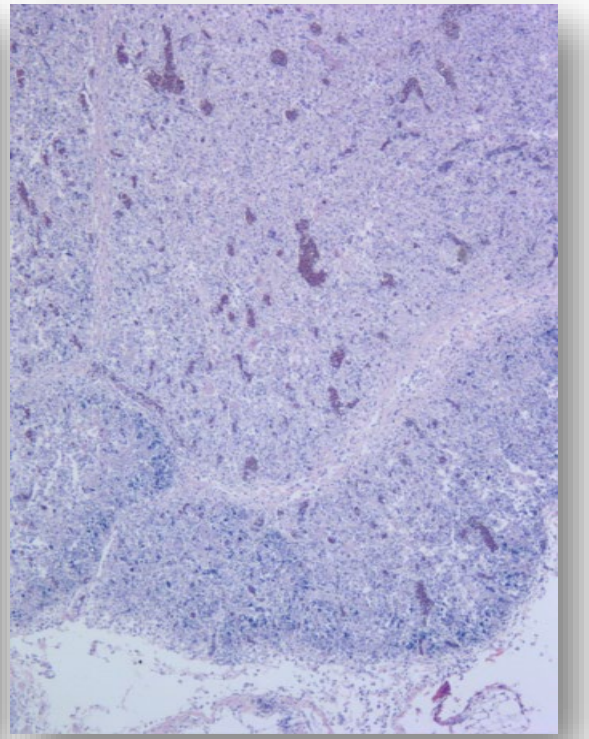

Thymus

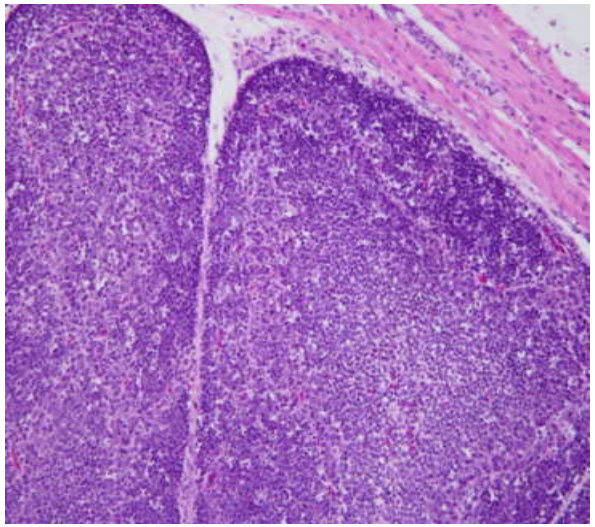

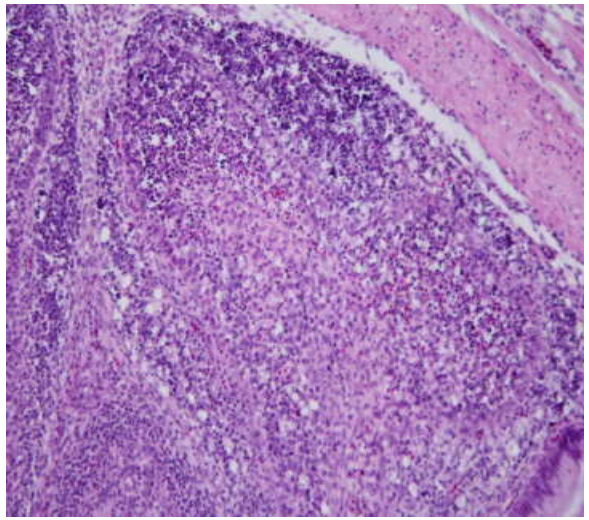

Stages of Bursal Disease: Histopathology

- **Normal Bursa**
- **Virus infection, acute necrotizing phase**
  - Lymphocyte necrosis/apoptosis –rapid progression
  - Strain variable
    - Apoptosis and lymphoid depletion, absent or minimal inflammation
    - Hemorrhage, edema, granulocytic and histiocytic inflammation
  - Cytotoxic T cells rapidly enter and associated with decline of viral load
  - End point: the lymphocyte population is destroyed
- **Follicular restitution phase**
  - Absent to substantially complete
  - Small undifferentiated follicles, lower immunocompetence
  - Large differentiated follicles, higher immunocompetence

NORMAL

ACUTE PHASE – Necrosis/Apoptosis

RECOVERY PHASE – Follicular Restitution

0 1 2 3 4 5 5 4 3 2 1 0

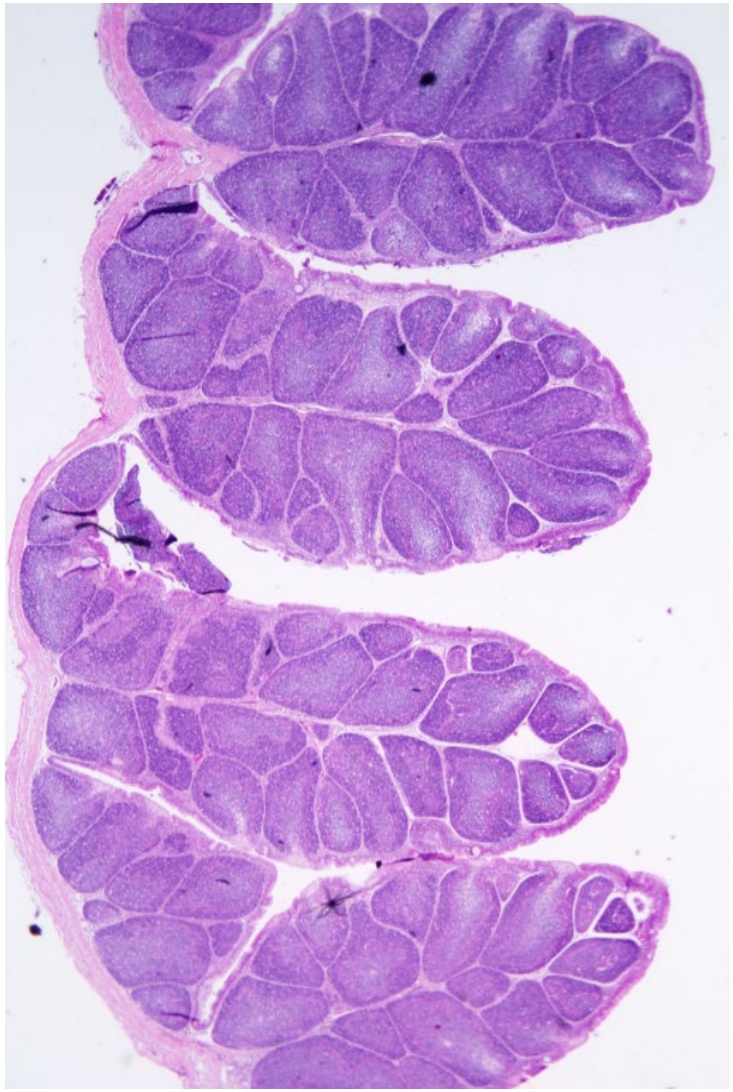

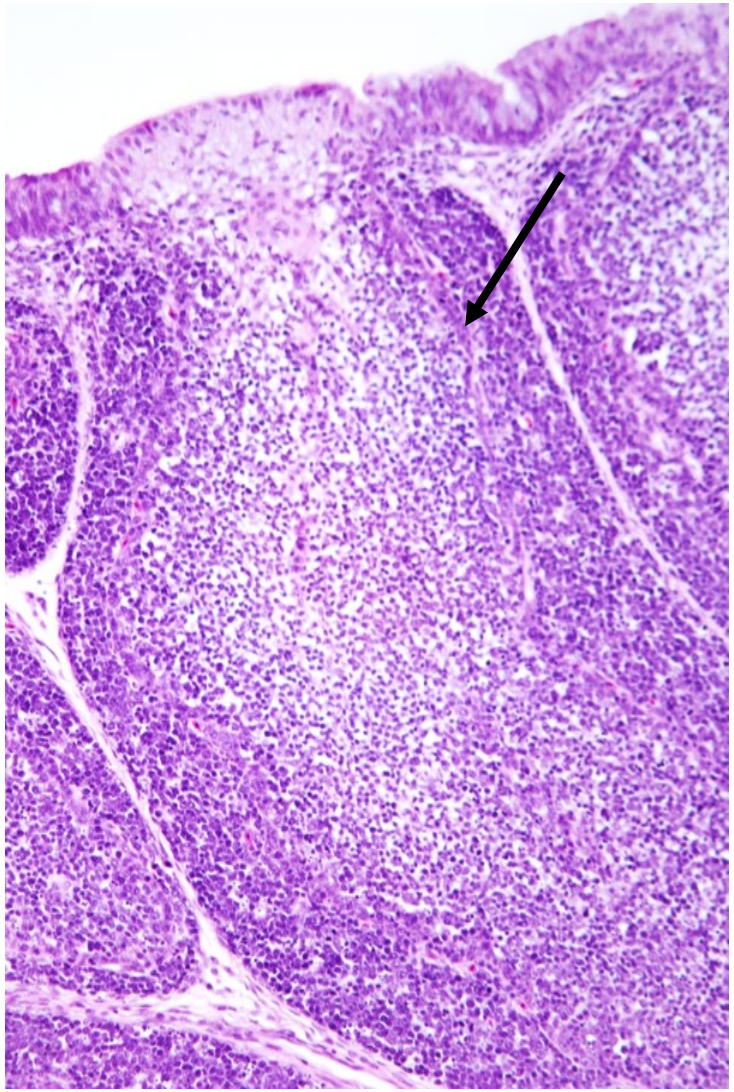

NORMAL

ACUTE PHASE – Necrosis/Apoptosis

RECOVERY PHASE – Follicular Restitution

0 1 2 3 4 5 5 4 3 2 1 0

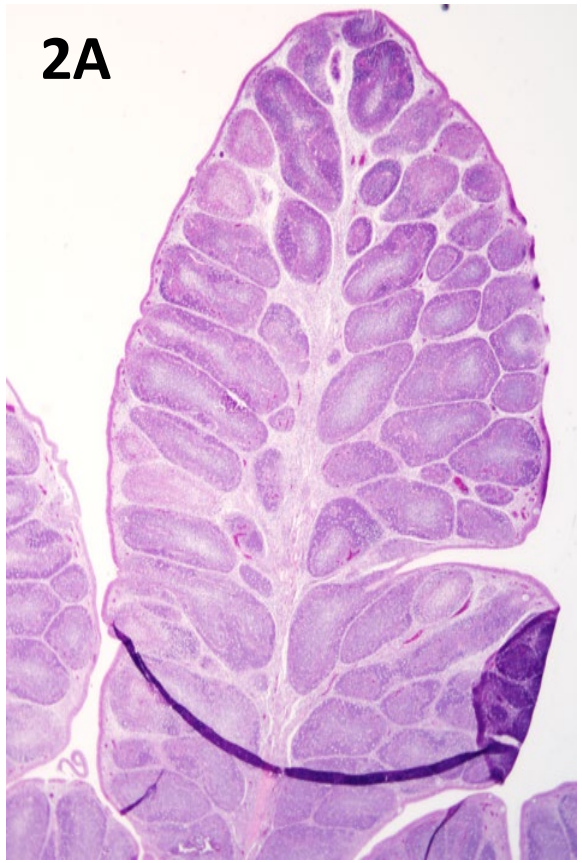

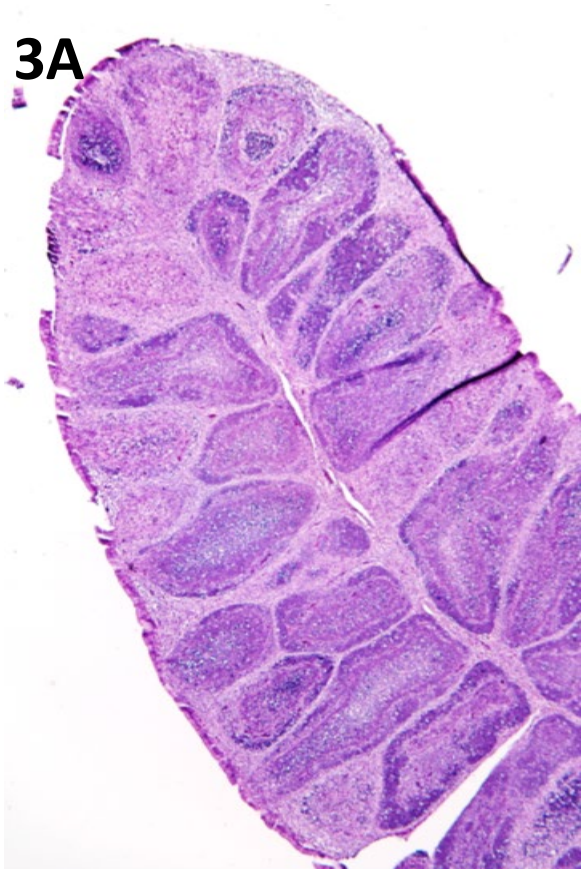

Stages of Infectious Bursal Disease

Acute Phase

Recovery Phase

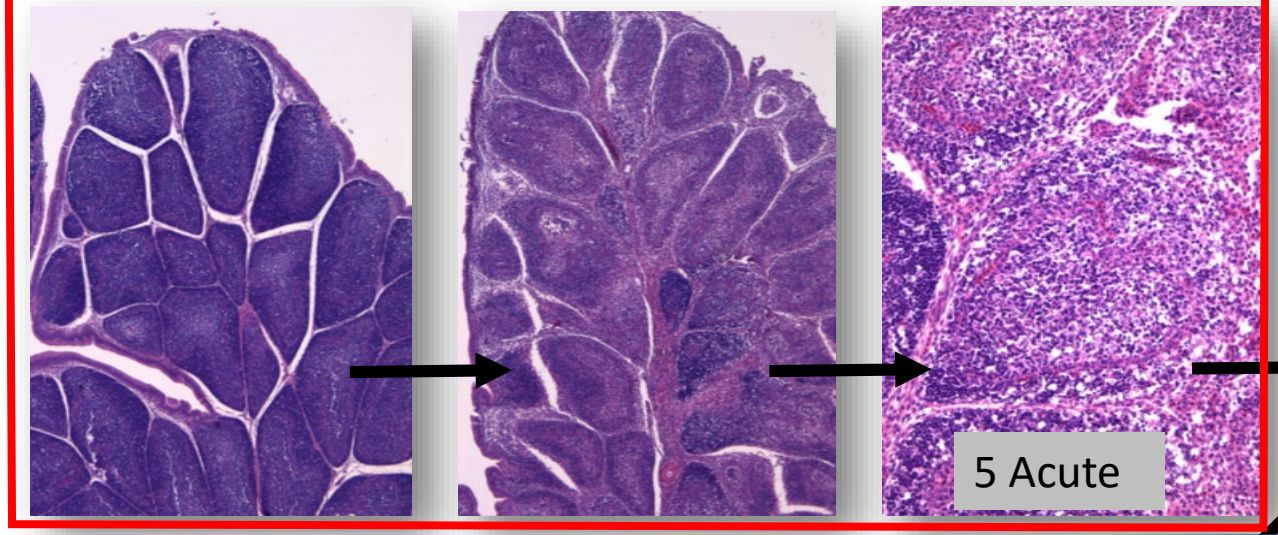

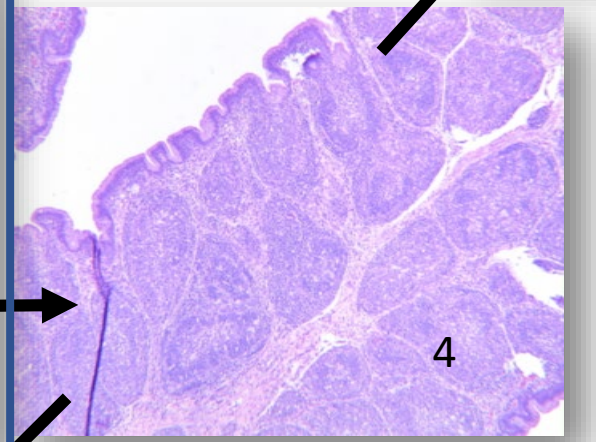

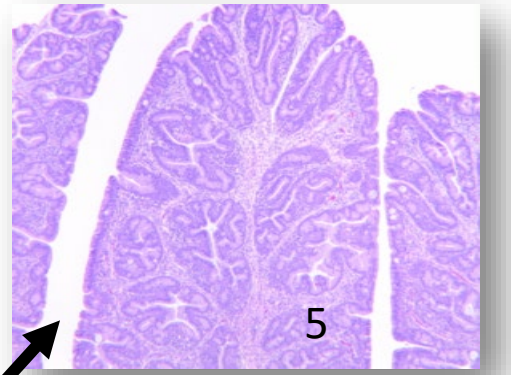

Normal

Score 0

Diffuse necrosis
(Score 5, acute)

Follicular Restitution

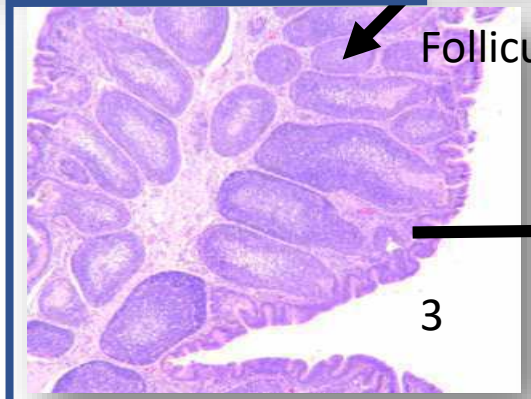

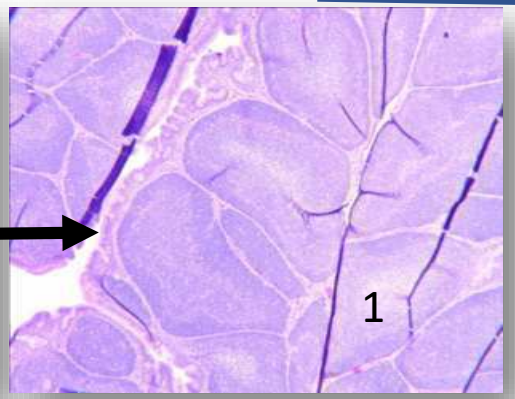

Post Bursal Disease Follicular Restoration Small vs. Large Follicles

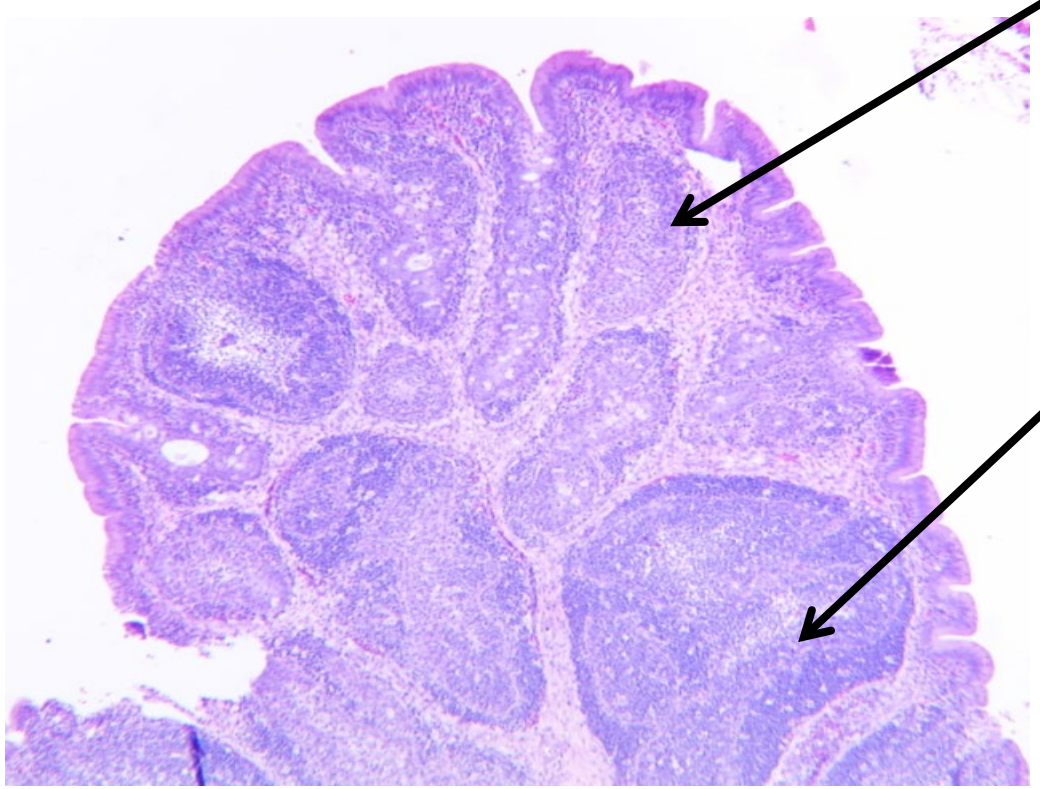

- **Small undifferentiated follicles**
  - Lymphocyte restoration from medullary stem cells
  - Minimal or no immune response capability
- **Large follicles**
  - Rapidly proliferating B cells
  - Correlated with partial recovery of antibody response
    - *Withers et al. Immunology 117, 558-565, 2006*
  - The antibody response does not occur in the bursa
    - *M. E. Ifrah et al. Poultry Science 96, 2017*

Age of Immune Injury

Bursa and Thymus: Critical First 14 Days

Primary lymphoid organs seed secondary organs

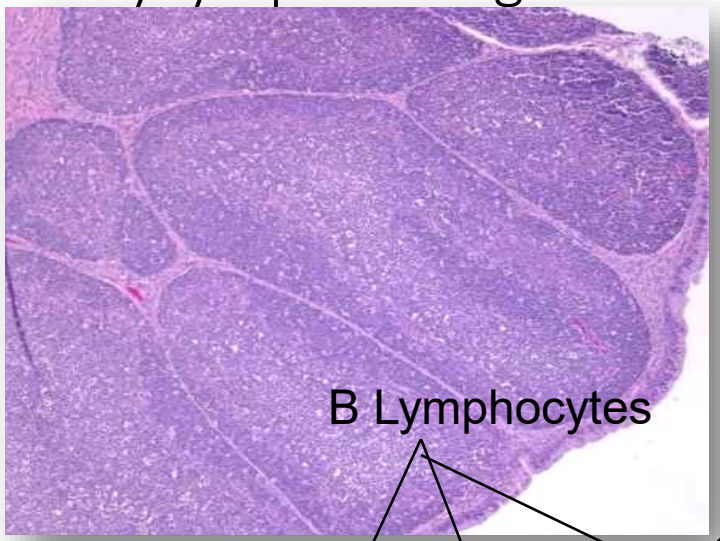

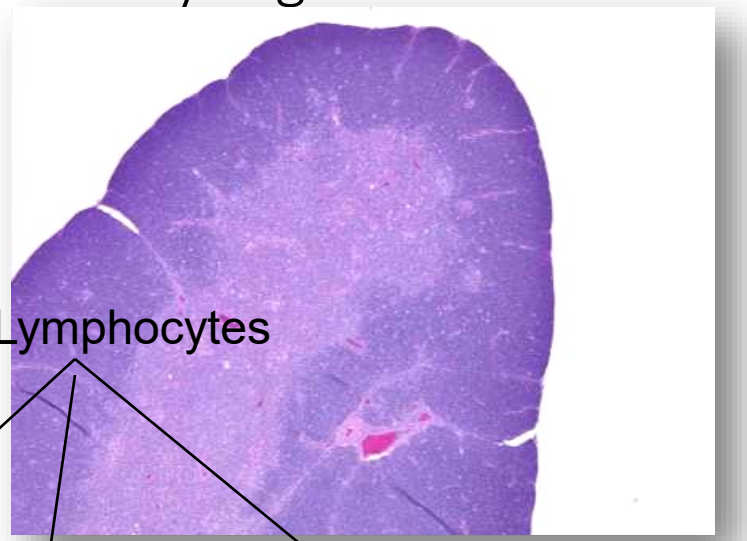

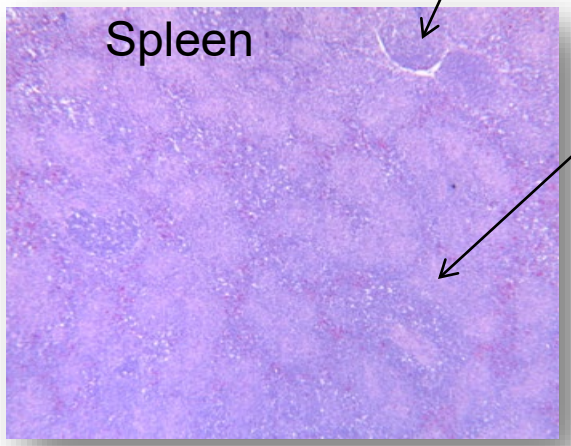

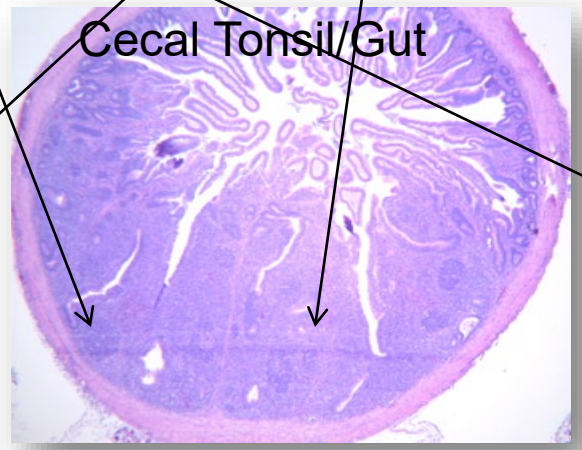

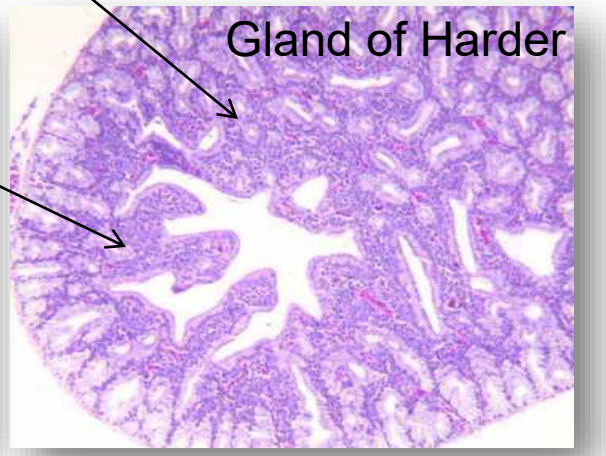

Bursa Survey: 6 flocks – Spleen Germinal Centers (B-cell centers)

Age	Units	B1	B2	B3	B4	B5	B6	Mean	Virus Detect	#Nec	Comment
14	days	1	1	1	1	1	1	1		0	Within normal limits
21	days										Tissue not available
29	days	3.5	3.5	3.5	3.5	2	2	3	2	0	Recovery IBD
34	days	3	3	3	3.5	3	1	2.75	2	0	Recovery IBD
41	days	3	3	3	3	3	1	2.6667	2	0	Recovery IBD
14	days	1	1	1	1	1		1			Within normal limits
21	days	1	1	1	1	1		1			Within normal limits
28	days	4	4	1	4	4		3.4	1	4	Acute bursitis/IBD
33	days	3.5	3.5	3.5	3	3.5		3.4	2	0	Recovery IBD
41	days	3	3	3	3	3		3	2	0	Recovery IBD
41	days	3	3	3	3	3		3	2	0	Recovery IBD
14	days	1	1	1	1	1		1			Within normal limits
21	days	4	4	3.5	1	1		2.7	1	3	Acute bursitis/IBD
28	days	4	3.5	4	3	3		3.5	2	0	Recovery IBD
33	days	3	3	3	3	3		3	2	0	Recovery IBD
41	days	2.5	3	3	3.5	3		3	2	0	Recovery IBD

25.8

16.6

18.8

14	days	1	1	1	1	1		1			Within normal limits
22	days	1	1	1	1	1		1			Within normal limits
29	days	3	3	3.5	3.5	3.5		3.3	2	0	Recovery IBD
34	days	3	3	3.5	3	3		3.1	2	0	Recovery IBD
41	days	3	3	3	3	2.5		2.9	2	0	Recovery IBD
41	days	3	2.5	3	3	3		2.9	2	0	Recovery IBD
14	days	4	1	1	1	1		1.6	1	1	Acute bursitis/IBD
21	days	3	3.5	3.5	3.5	3.5		3.4	2	0	Recovery IBD
28	days	3.5	3.5	3.5	3.5	3.5		3.5	2	0	Recovery IBD
32	days	2.5	2.5	2.5	2.5	3		2.6	2	0	Recovery IBD
41	days	2.5	2.5	2	2	2.5		2.3	2	0	Recovery IBD
41	days	1	2.5	2.5	2.5	2.5		2.2	2	0	Recovery IBD
14	days	1	1	2	1	1		1.2	1	1	Acute bursitis/IBD
21	days	4	4	4	4	3.5		3.9	1	4	Acute bursitis/IBD
28	days	3	3	3	3	3		3	2	0	Recovery IBD
33	days	2.5	4	2.5	3	3		3	2	0	Recovery IBD
41	days	2.5	2.5	1	2.5	2.5		2.2	2	0	Recovery IBD
41	days	2.5	1	2.5	2.5	2.5		2.2	2	0	Recovery IBD

11.6

4.2

7.2

Thymus Pathology: Lymphocyte Depletion

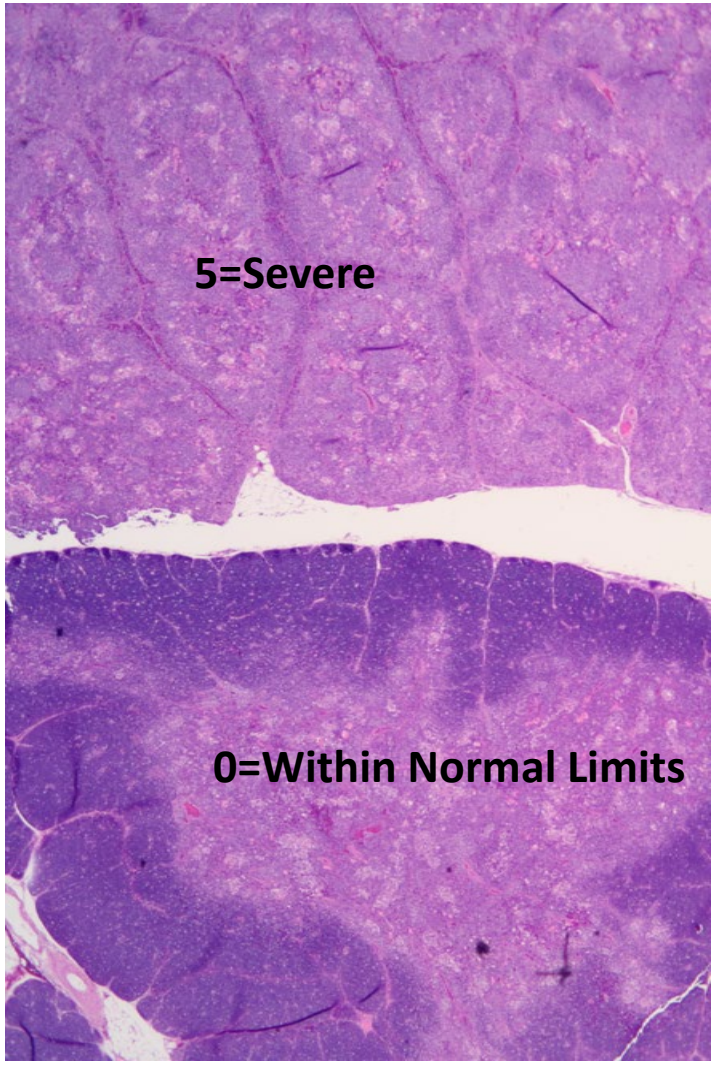

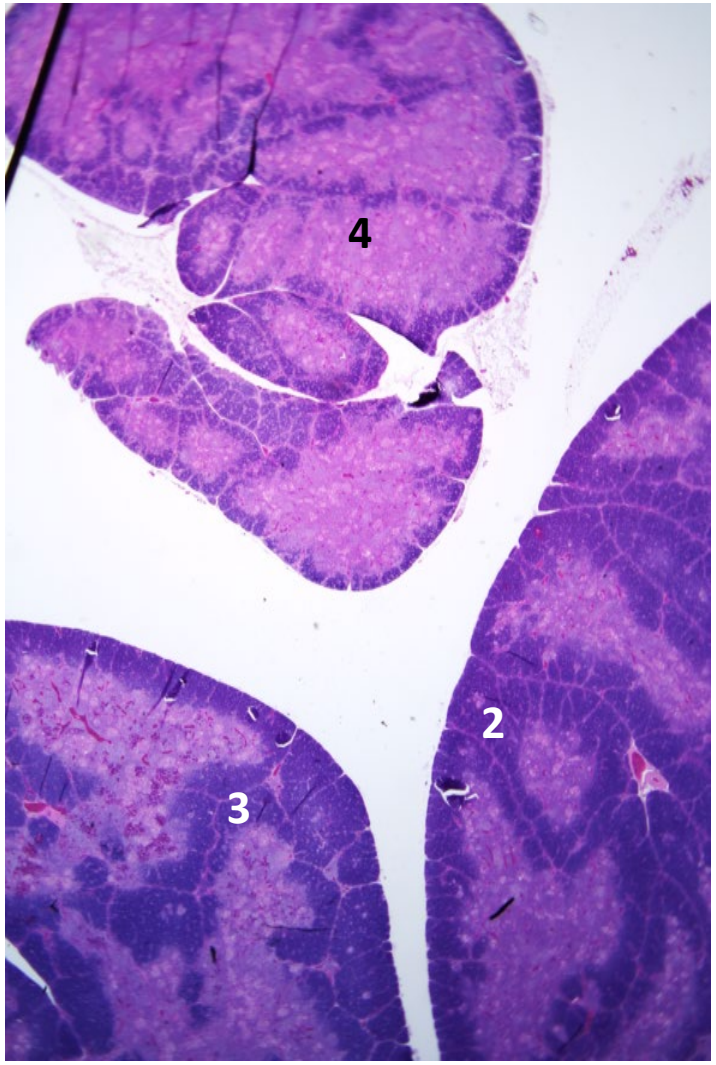

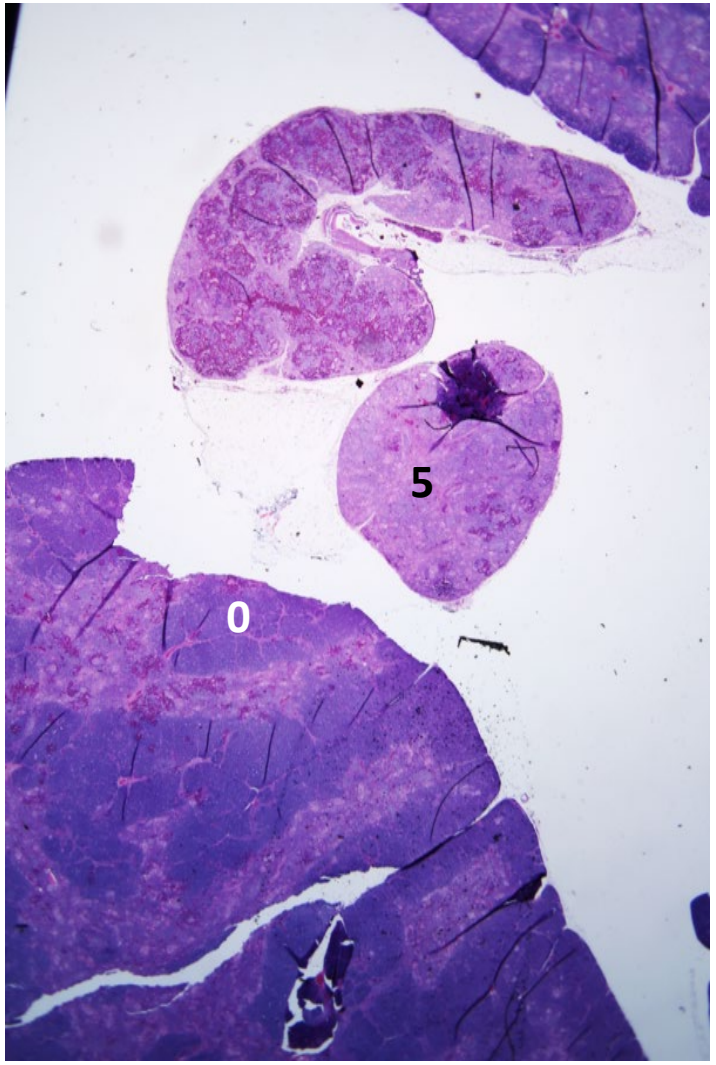

Immune Surveys by Histopathology October 2018-October 2019

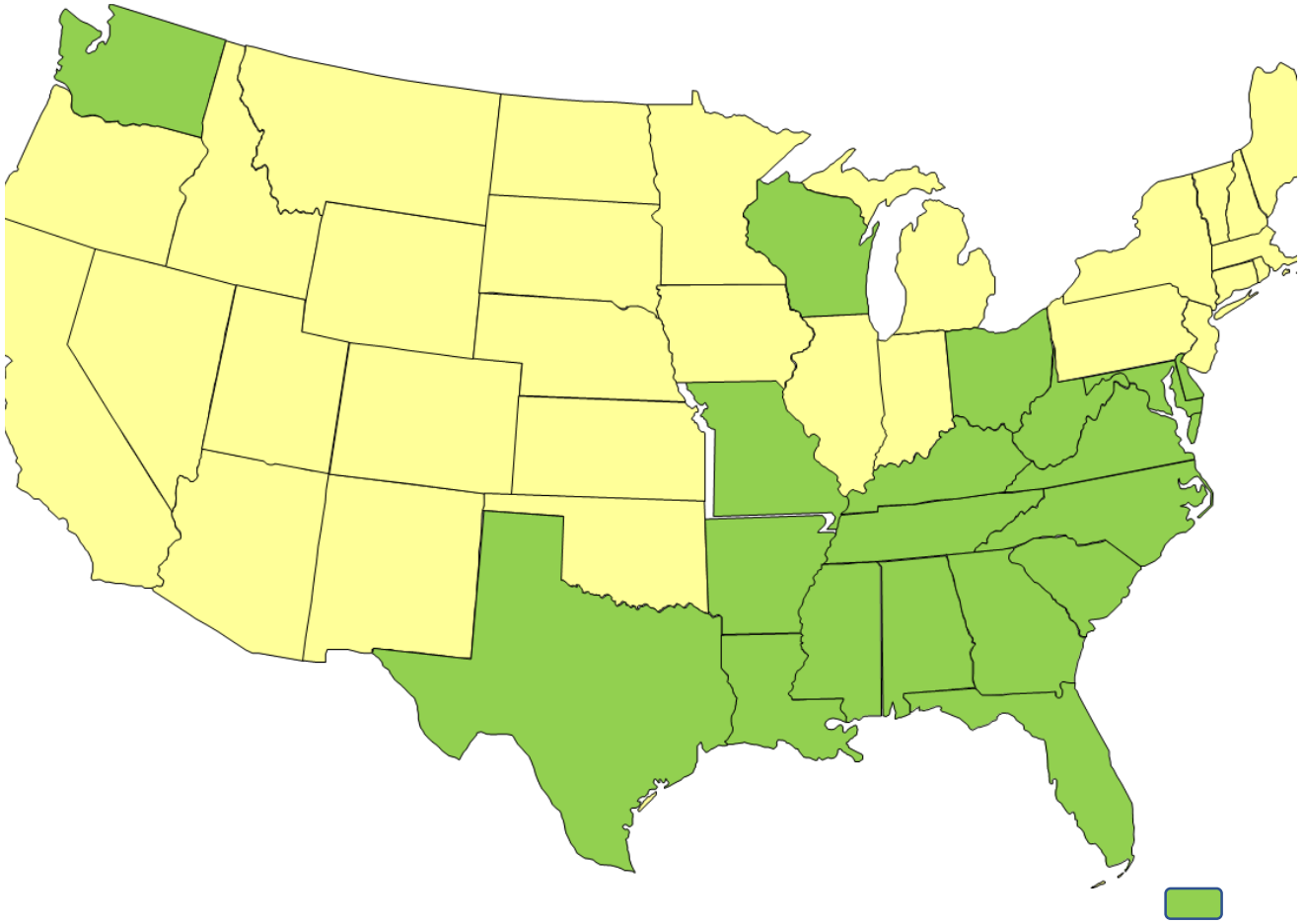

- Bursa: **1438** US Broiler flocks
  - Thymus & Spleen **~370** flocks
- Survey designs
  - 21 days (bursa only)
  - 12 - 24 days (mostly bursa, some thymus)
    - ~2 day intervals
  - 12 – 45 day+, bursa, also thymus and spleen
    - ~3 day intervals
- 21 states and territories
- Clinically normal chickens
  - 5-7 birds sampled per flock
  - 10-15 flocks per survey
- Pathologist blinded to vaccination program
- Data in Excel, pivot table analysis

Bursa by Age and Lesions

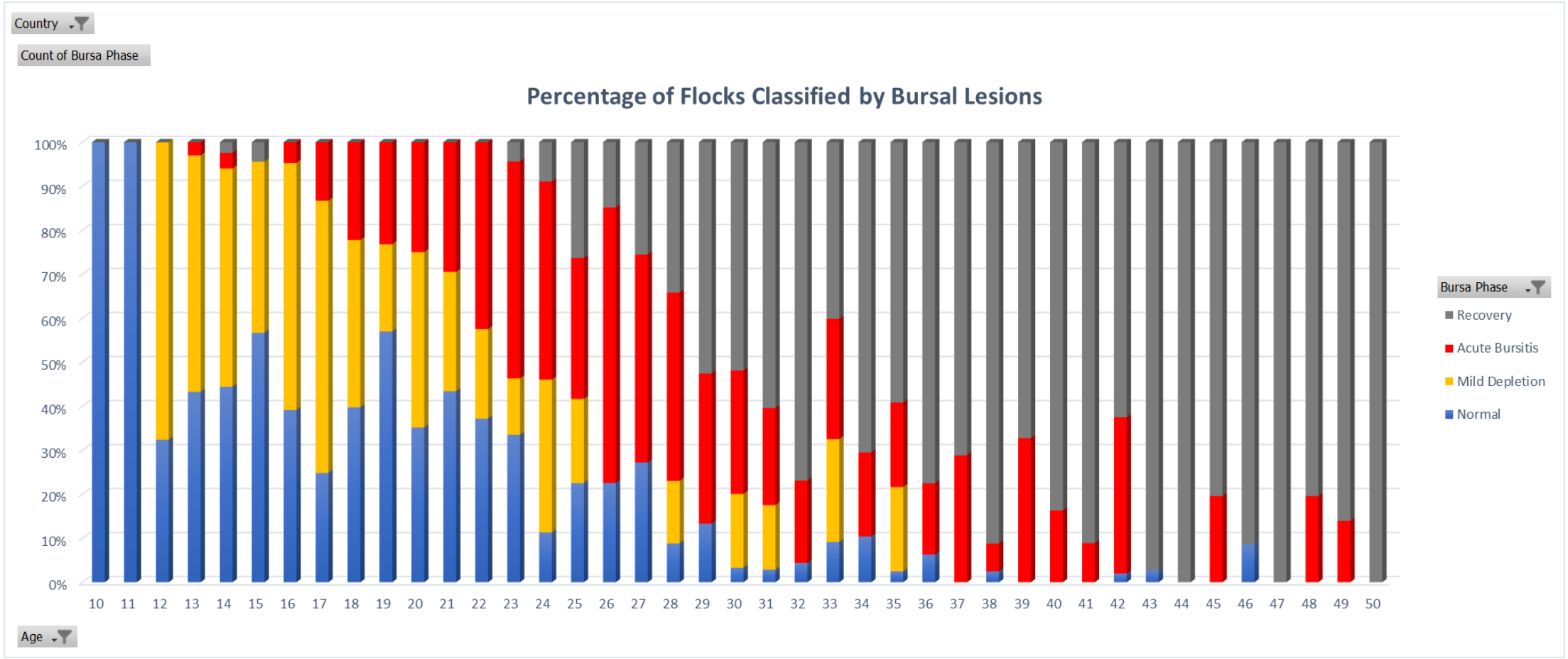

Bursa by Age and Bursa Score Trends

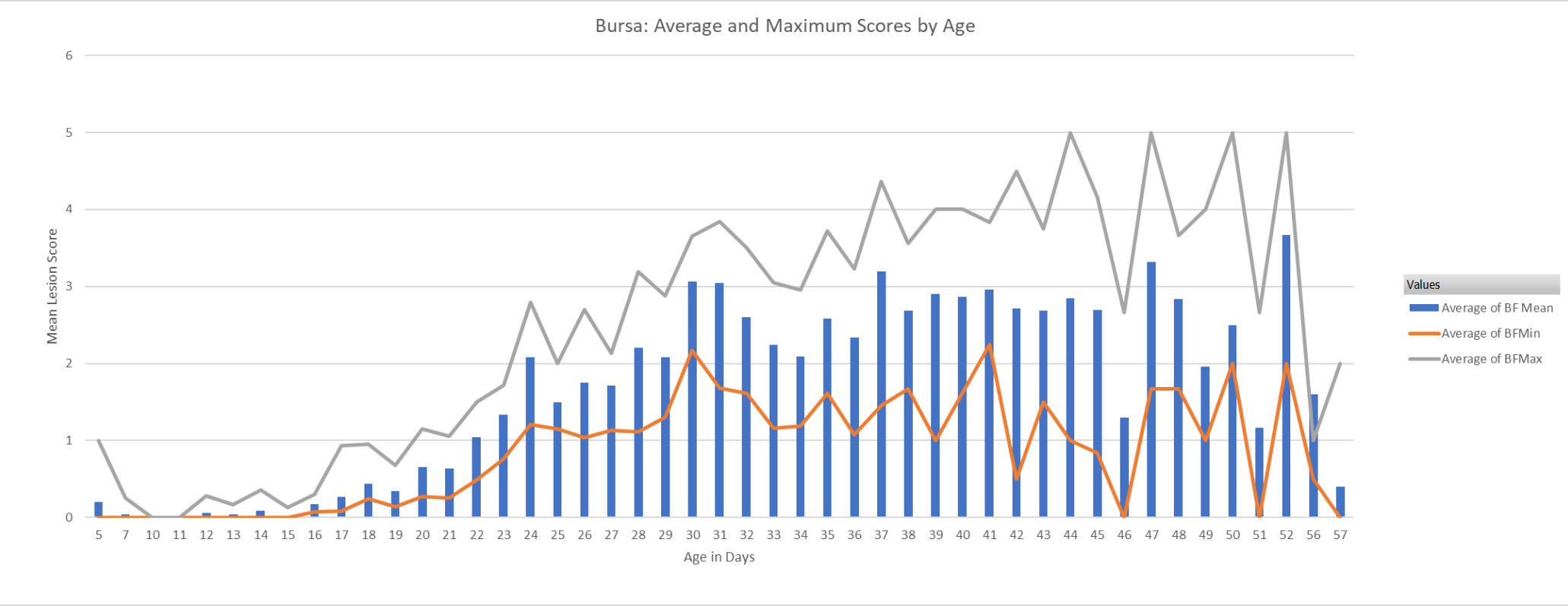

Thymus by Age and Lesions

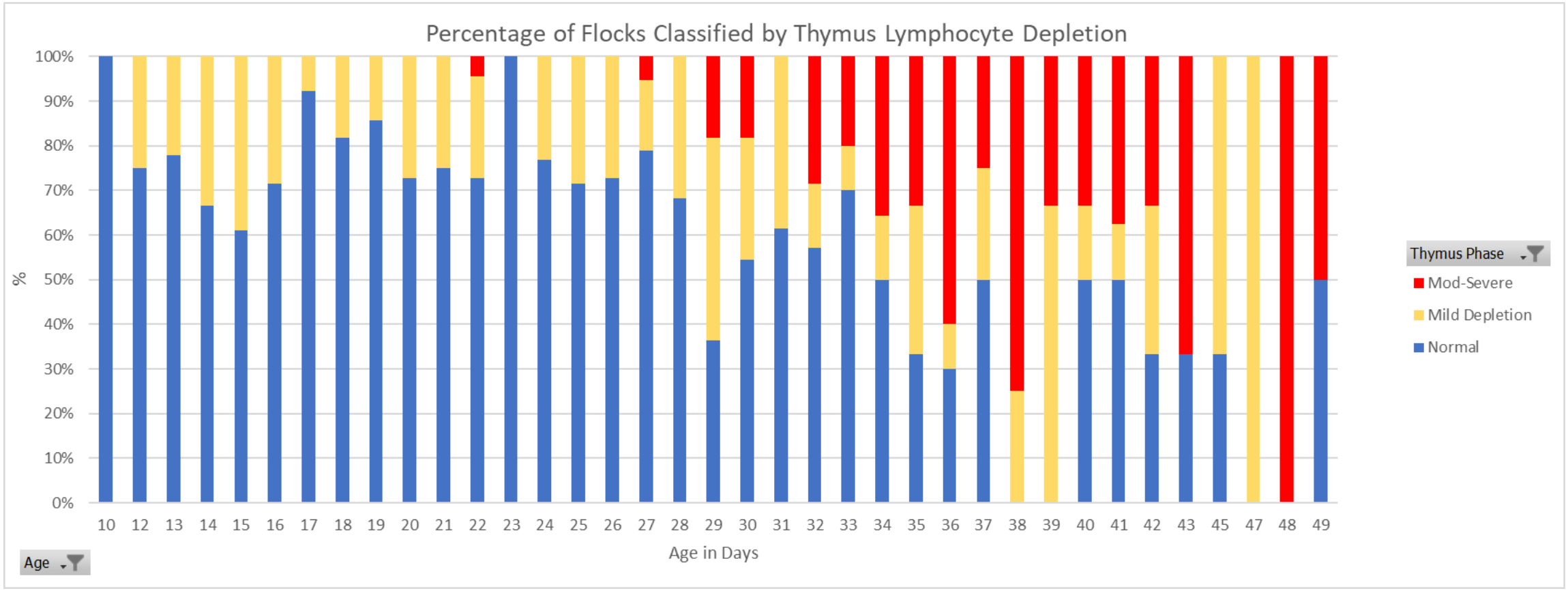

Thymus by Age and Thymus Lymphocyte Depletion Trends

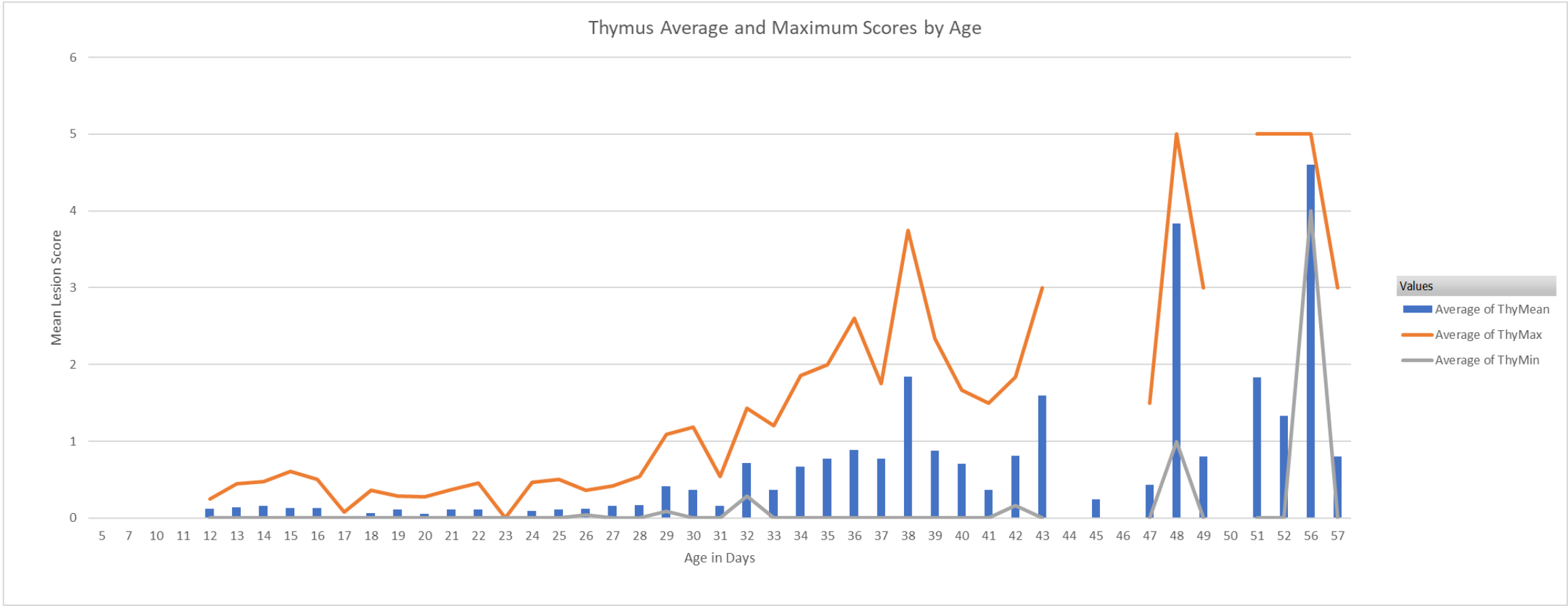

Bursa and Thymus Lymphoid Depletion Trends

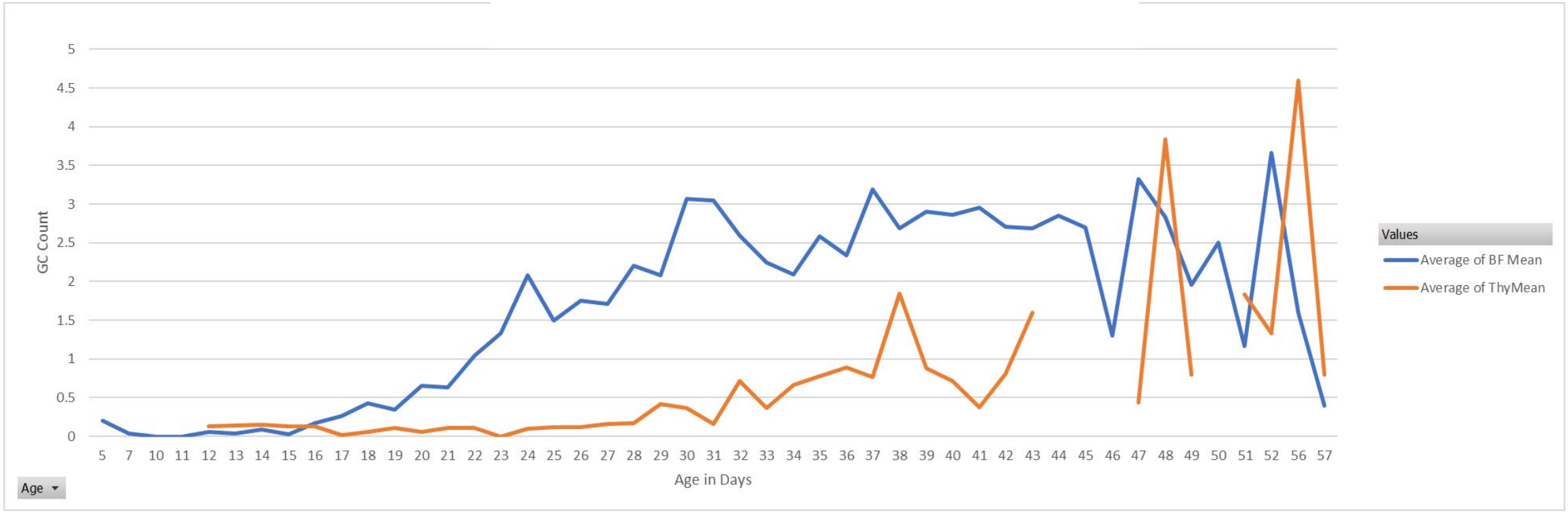

Alabama Broilers 1990's

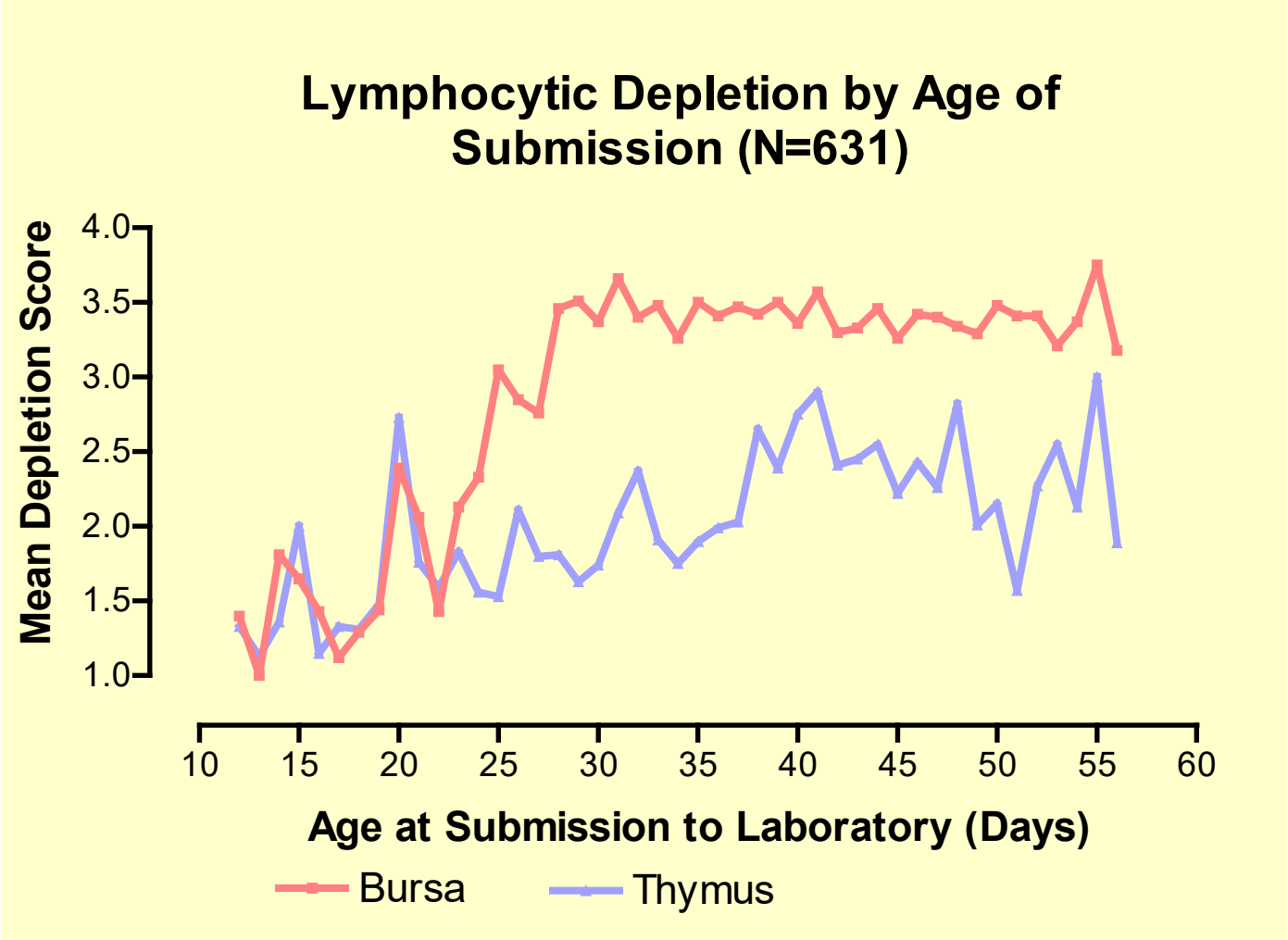

CAV Infection& Thymus Atrophy after Depleted Maternal Immunity

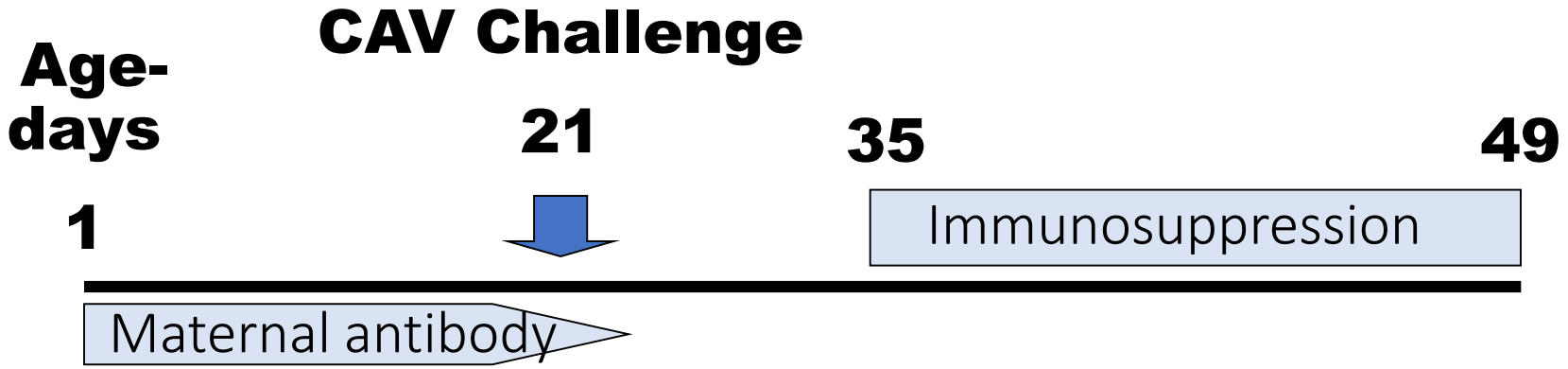

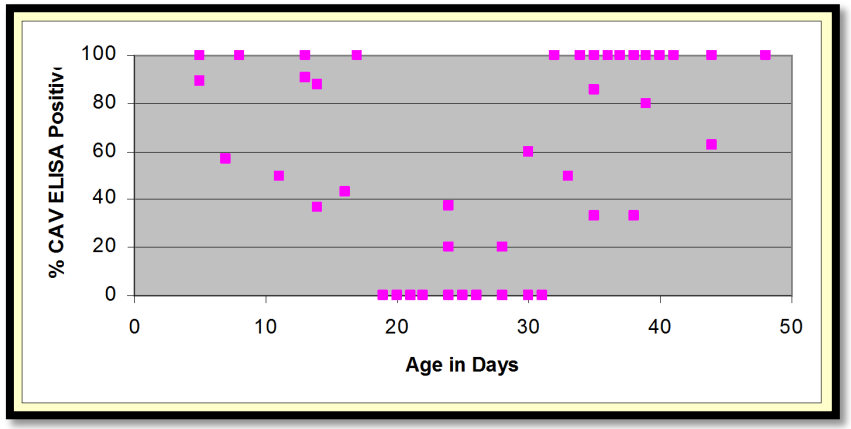

- No anemia observed
- Lymphocyte and macrophage suppression
  - T-cell growth factor, interferon, and transformation
  - Macrophage FC receptor expression, interleukin-1, phagocytosis and bactericidal activity

McConnell, Adair & McNulty (Avian Dis 37:366-374, 1993)

Summary of 6-year Study: Alabama Broilers

- CAV infection was widespread
- Thymus atrophy associated with CAV infection
- CAV, thymus atrophy, and bursa atrophy were more prevalent in chickens with clinical disease
  - Respiratory
  - Gangrenous Dermatitis
  - Coccidiosis

Hagood et al. Avian Dis 44:803-808. 2000.

Laboratory findings correlated with economic losses.

Thymus and Bursa Lymphocyte Depletion

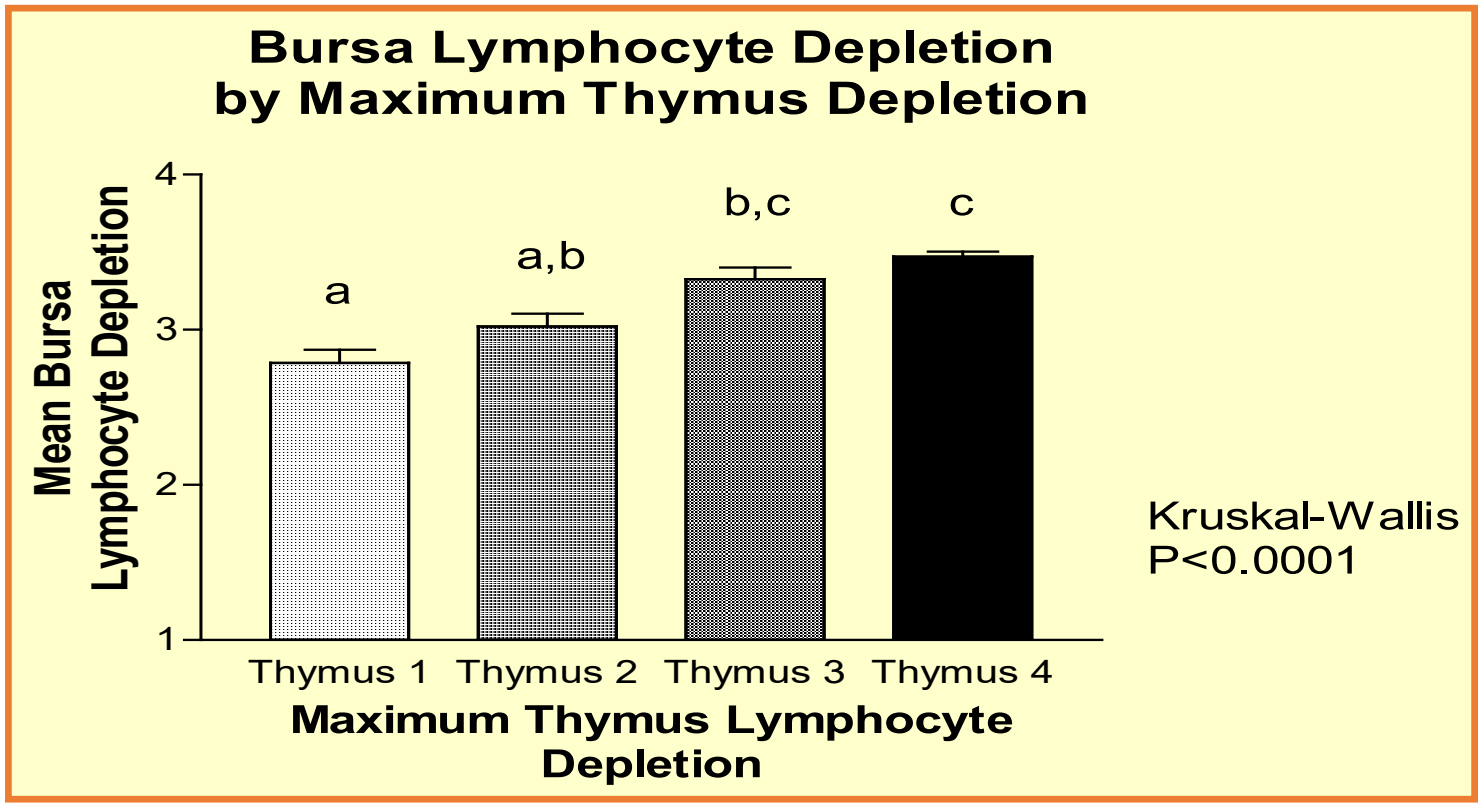

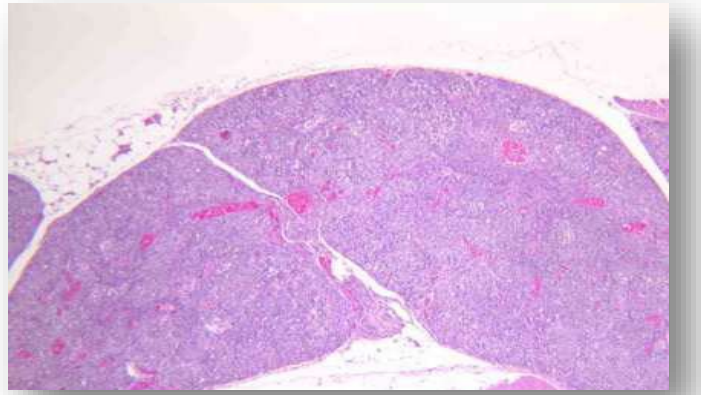

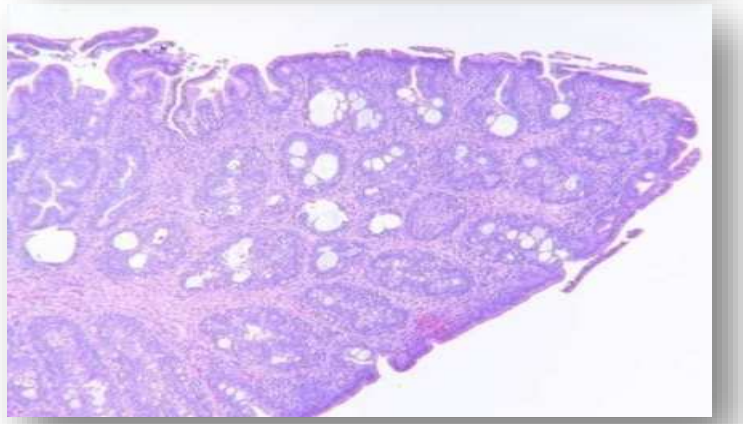

Spleen Germinal Center Trends

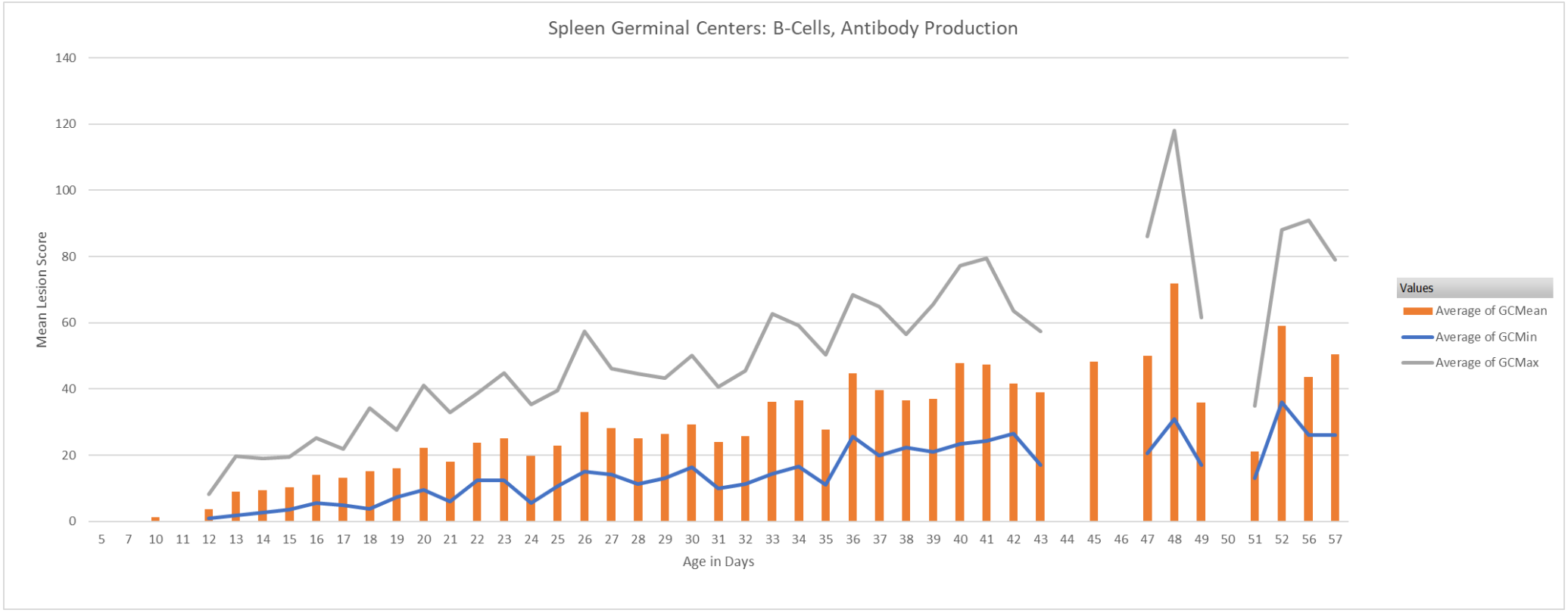

Spleen Germinal Center Trends by Bursal Lesions

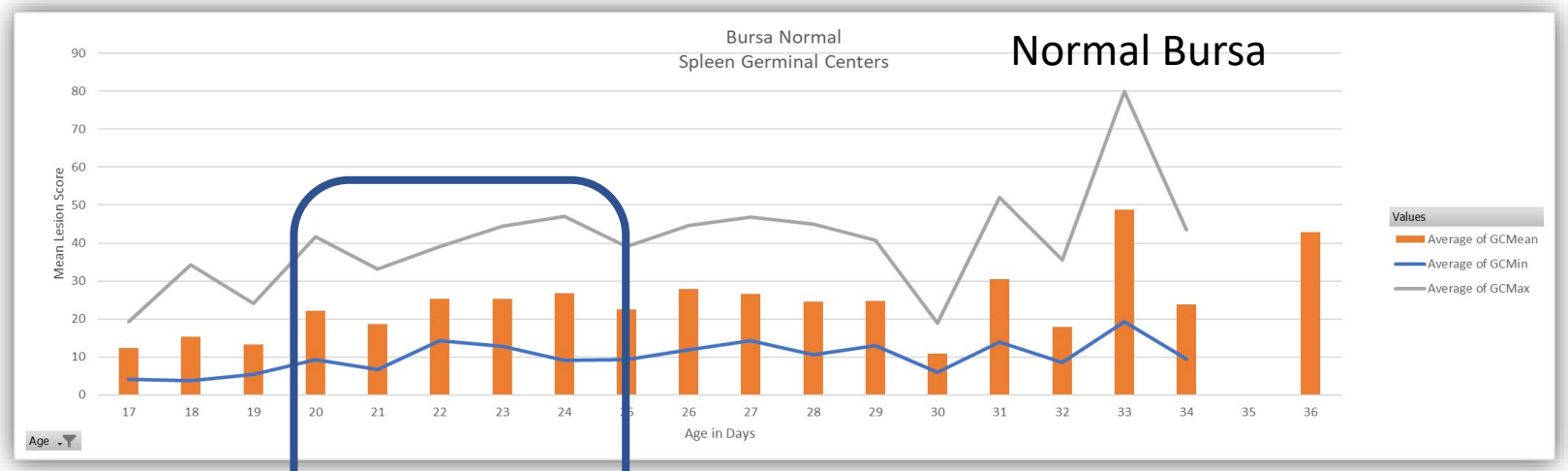

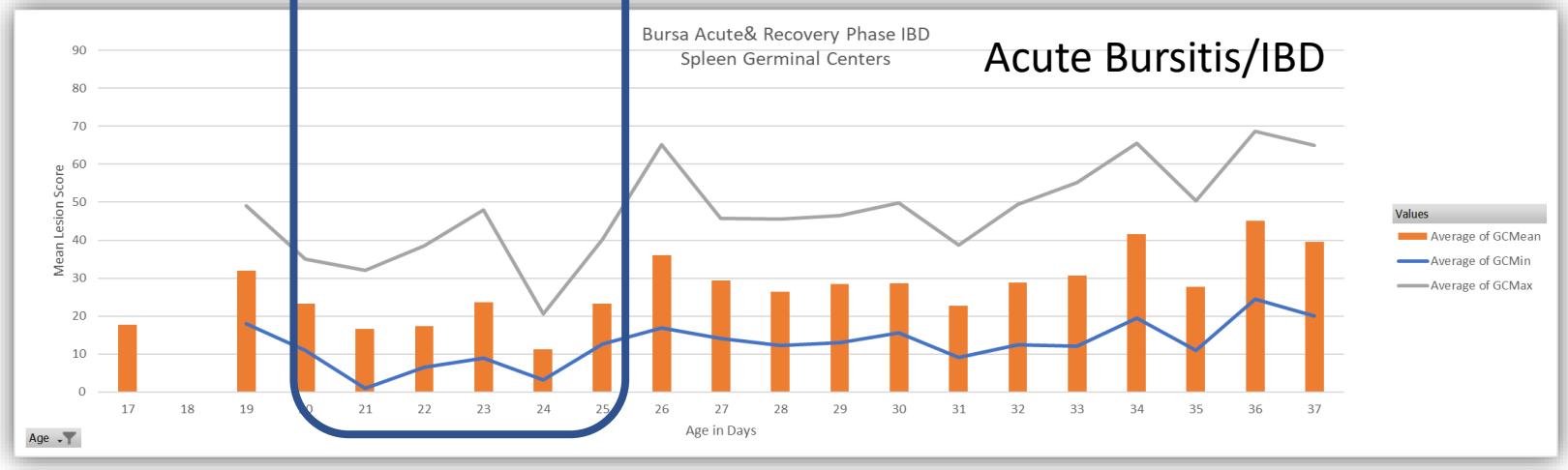

Bursa and Spleen Interaction 20-25 days

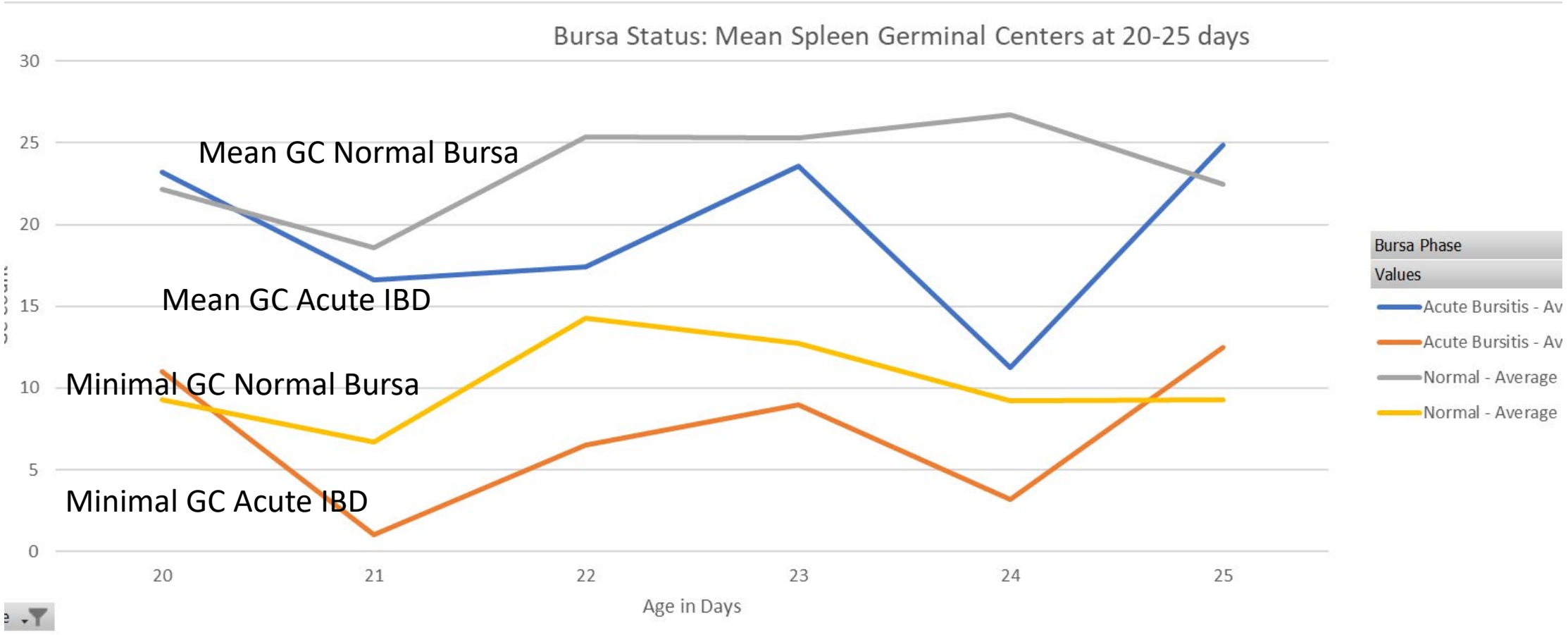

Decreased Germinal Centers at 20-25 days

- Reduction in antibody production in spleen and other GC-rich tissues
  - Gut, conjunctiva, bronchi, biliary tract
- Gut is acquiring mature function
  - E. maxima peak scores at 26-27 days
- Respiratory vaccine virus shedding and reaction
- Potential determinate of severity of reovirus infection (tenosynovitis)

Immunosuppressive Interactions in Broilers

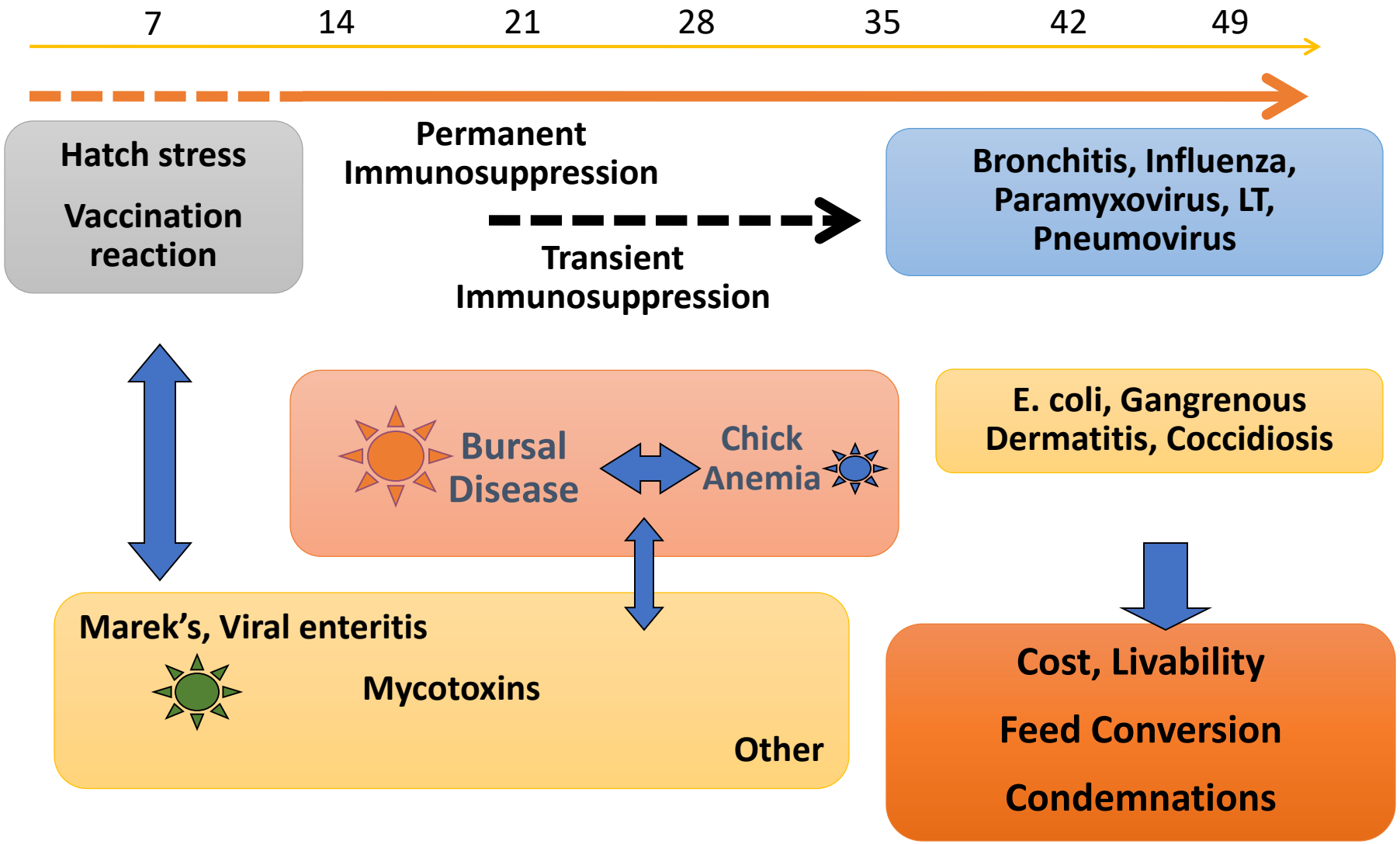

END

Fred.hoerr@gmail.com
www.vetdx.com
334-750-7566
638 South Fort Valley Rd
Fort Valley, VA 22652

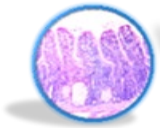

Veterinary Diagnostic Pathology, LLC
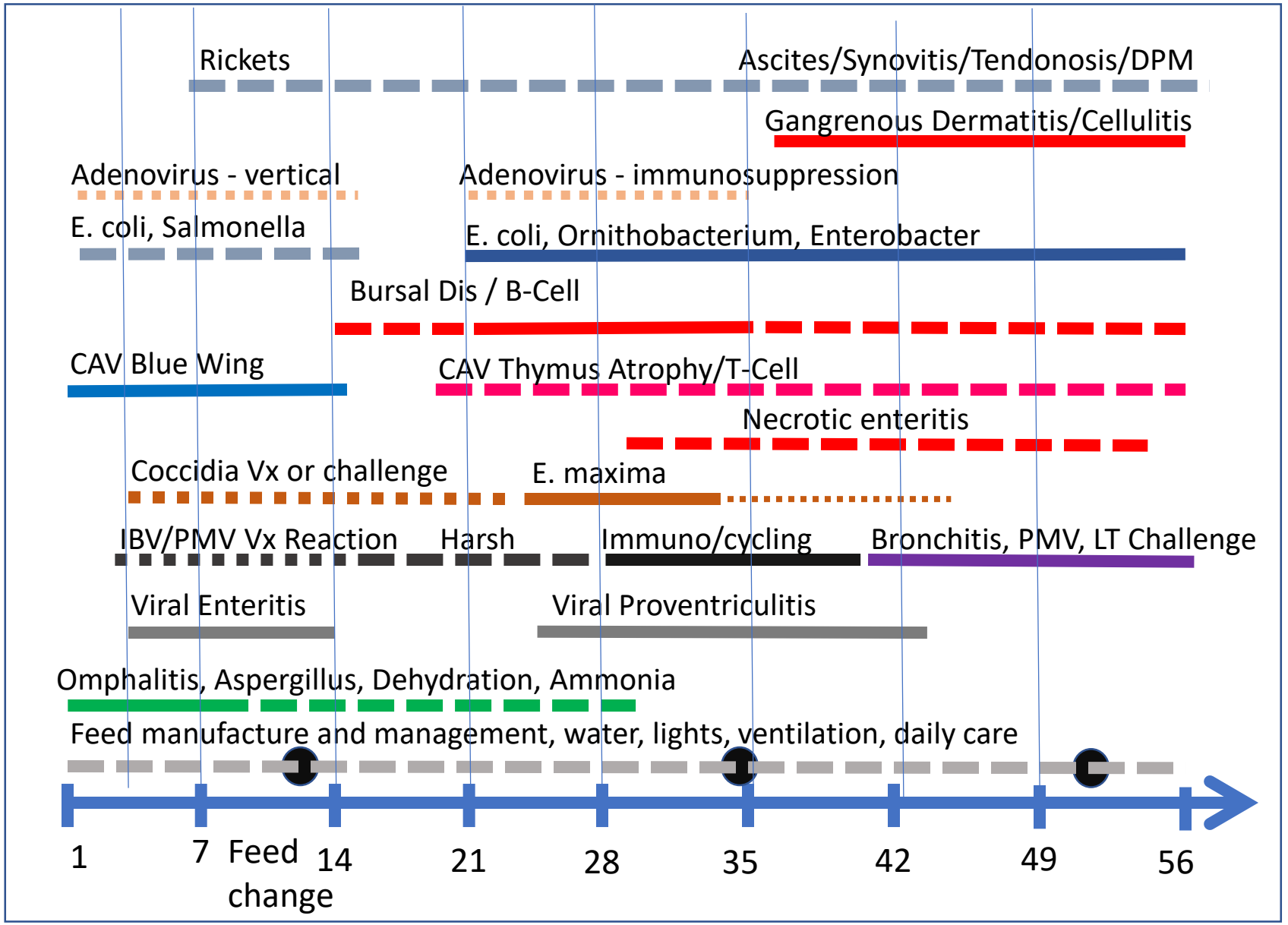
Histopathology of Broiler Disease by Age